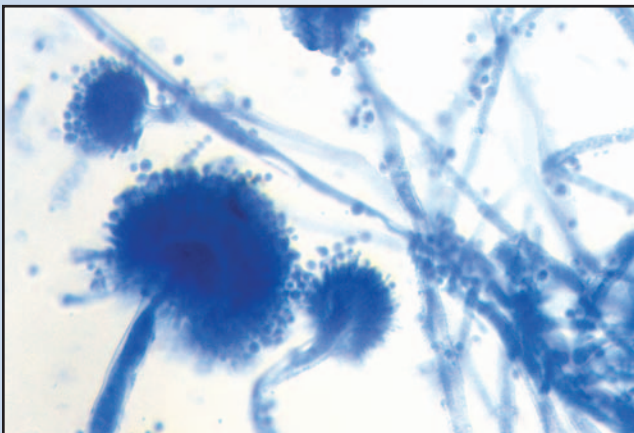


# Implications of Mycoses in Clinical Disorders

ROBERT D. DAHLHAUSEN, DVM, MS



**Fig 29.1** | New methylene blue stain of *Aspergillus* conidial chains from an air sac sample obtained at endoscopy.

Mycotic infections are relatively common in avian species. Many fungal agents exist in the environment as soil-borne saprophytes. Most birds are exposed to them in their normal habitat or aviary environment without effect. Nutritional disorders in parrots, stress of captivity in raptors and incubation-related disorders in hatchling galliforms, along with other causes of impaired immune function and environmental factors conducive to fungal proliferation, can cause disease to occur. Respiratory tract aspergillosis and alimentary tract infections due to *Candida* and other yeasts are the most frequent forms of fungal disease observed. The early diagnosis and successful management of systemic fungal disease can present a diagnostic and management challenge to the avian practitioner. Advances in diagnostic methods, improved knowledge of therapeutic agents and better management practices have reduced the morbidity and mortality associated with these agents.

## Aspergillosis

Aspergillosis is a non-contagious, opportunistic infection referring to any disease condition caused by members of the fungal genus *Aspergillus*. The organism is an opportunistic, angio-invasive fungus that may act as an allergen, colonizer or invasive pathogen. It can produce both acute and chronic disease varying in spectrum from local involvement to systemic dissemination. It is the most frequent cause of respiratory disease and the most commonly diagnosed fungal disease in pet birds.<sup>70</sup> It also is considered the most common, non-traumatically-induced medical problem in free-ranging birds of prey.<sup>92</sup> The disease is known to occur in a wide variety of captive and free-living birds. Almost all avian species should

be considered as potential hosts susceptible to *Aspergillus* infection.<sup>2</sup>

## EPIDEMIOLOGY

*Aspergillus* spp. are ubiquitous fungi commonly found in nature in the environment, soil and feed grains. They are distributed worldwide and proliferate in environments with high humidity and warm (>25° C) temperatures.<sup>62</sup> Moldy litter, grain and bedding material contaminated with feces are common media for fungal growth. *Aspergillus fumigatus* is the most commonly isolated species from birds with aspergillosis, followed by *A. flavus* and *A. niger*.<sup>22,56</sup> *Aspergillus clavatus*, *A. glaucus*, *A. nidulans*, *A. oryzae*, *A. terreus*, *A. ustus* and *A. versicolor* are among the other species less commonly isolated.

## DISEASE PREDISPOSITION

Susceptibility to disease is greatly increased when the immune system is impaired. Immunosuppression is the major factor predisposing birds to the development of opportunistic *Aspergillus* infections. *Aspergillus* spores are widespread in the environment, and many birds may carry them in their lungs and air sacs until immunosuppression or stress triggers clinical disease (Fig 29.1).

Stress alone (a strong immune suppressor) or other factors related to confinement, poor husbandry practice, malnutrition, pre-existing disease and the prolonged use of antibiotics and steroids increase the predilection to disease.<sup>73,95</sup> Overpopulated, poorly ventilated and dusty aviary environments lead to pulmonary and air sac disease. Research has confirmed a causal relationship between high concentrations of *Aspergillus* spp. spores in the environment and aspergillosis. Damp feed or bedding in warm, humid environments and poor ventilation allow for a high concentration of *Aspergillus* spores to develop.<sup>87</sup> Corncob and walnut shell litters can grow *Aspergillus* spp. in aviary environments. Inhalation of large numbers of spores may occur. Birds exposed to the organism in quantities sufficient to establish a primary infection have developed acute disease. There is often a correlation between poor husbandry and a high concentration of spores. Eucalyptus leaves, which have been promoted as a "natural" insect repellent, are often heavily contaminated with this fungus. Acute, severe, untreatable aspergillosis has been associated with their use.<sup>43</sup> Aspergillosis is a common sequela to other respiratory tract disease. A predominantly seed diet, with subsequent malnutrition including vitamin A deficiency, can lead to squamous metaplasia of the oral and respiratory epithelium and the establishment of fungal growth.<sup>73</sup> The incidence of fungal disorders is negligible in an avian practice where the majority of parrots are fed a

formulated diet (G.J. Harrison, personal communication, 2003) (see Chapter 4, Nutritional Considerations).

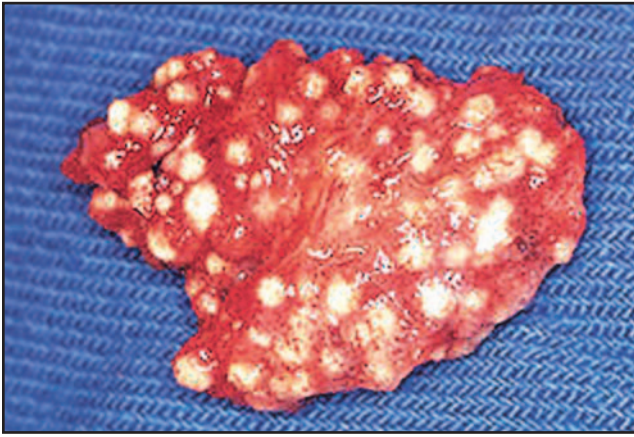Aspergillosis is the most commonly occurring respiratory disease in captive wild birds.<sup>95</sup> Of the psittacine species, the African grey parrot (*Psittacus erithacus*) and pionus parrots (*Pionus* spp.) are reported to have an increased susceptibility to the development of disease.<sup>9</sup> Localized infection of the nasal passages is observed in Amazon parrots, possibly due to the higher incidence of hypovitaminosis A in this species.<sup>9</sup> Raptorial species at particularly high risk of developing aspergillosis include goshawks (*Accipiter gentilis*), rough-legged hawks (*Buteo lagopus*), immature red-tailed hawks (*Buteo jamaicensis*), golden eagles (*Aquila chrysaetos*) and snowy owls (*Nyctea scandiaca*).<sup>39,92,95</sup> Gyrfalcons (*Falco rusticolus*) are believed to be especially susceptible to *Aspergillus* infection<sup>39,42,92,95</sup>. Among waterfowl, a higher incidence of aspergillosis is seen in swans (*Cygnus* spp.). Captive penguins (*Sphenisciformes*) also are extremely susceptible to developing the disease. In these species, the increased incidence of aspergillosis may reflect environmental and husbandry deficiencies occurring in captivity and/or increased species susceptibility.

## ASPERGILLUS PATHOGENESIS

*Aspergillus* spp. are widespread in nature. Birds are exposed to fungal spores on a regular basis, and many carry them in their lungs and air sacs without ill effect. The nature of disease that occurs is thought to depend on the resistance of the avian host and the number and distribution of fungal spores.<sup>8</sup> Healthy birds exposed to high concentrations of spores can be resistant to infection, whereas immunocompromised patients can become severely affected by minimal exposure.<sup>48,122</sup>

Aspergillosis is usually contracted as the result of a susceptible host inhaling fungal spores. Oral ingestion of spores from moldy feeds may also occur. The fungus is, however, capable of penetrating broken skin and eggshells and can infect developing embryos during the incubation process.

In birds, aspergillosis is predominantly a disease of the lower respiratory tract that usually occurs secondarily to other disease or immunosuppressive processes. Acute and chronic forms of the disease can occur. Infections may be localized or diffuse, depending upon the distribution and growth of fungal organisms. Initial lesions occur mainly in the lungs and air sacs, although the trachea, syrinx and bronchi also may be affected. Infections may spread from the respiratory tract to pneumatized bone or enter the peritoneal cavity by direct extension through the air sac walls. The organism may reach various other tissues by vascular invasion and embolism. The fungus



**Fig 29.2** | Miliary lung nodules due to inhalation of *Aspergillus* spp. spores.

can infect any organ. Aerogenous and hematogenous dissemination result in diffuse, systemic disease.<sup>49</sup>

In the acute disease, whitish mucoid exudates of fungal growth are present in the respiratory tract. Marked congestion of the lungs and thickening of the air sac membranes occur. Miliary foci of inflammation develop around sites of fungal growth and result in the formation of micronodules (Fig 29.2).<sup>66,120</sup> These predominate in the caudal thoracic and abdominal air sacs and peripheral lung fields. In the chronic form of the disease, multiple nodules may coalesce into plaques and larger granulomatous lesions. Sporulating fungal colonies may develop in the center of these lesions, with extensive adhesions forming between the air sac membranes, lungs and abdominal viscera.

Some *Aspergillus* spp. produce mycotoxins that are immunosuppressive and may be involved in the pathogenesis of the disease. Some mycotoxins also possess carcinogenic activity. Of these, aflatoxin is well known and may induce hepatocellular carcinoma or hepatic fibrosis with subsequent cirrhosis when ingested. Aflatoxins are most commonly associated with *Aspergillus flavus* and may contaminate feeds such as peanuts.<sup>77</sup>

## DISEASE

Clinical signs associated with aspergillosis are variable and depend upon such factors as the pathogenesis of initial infection, location of lesions, organ systems involved and host immune defenses. The disease may be either localized or diffuse and often causes a progressive, debilitating illness with high mortality. Aspergillosis predominantly affects the upper and lower respiratory tract, however, any organ system may be involved. Both acute and chronic forms of infection are commonly recognized in birds.

## Acute Disease

Acute aspergillosis is a fatal respiratory disease characterized by variable morbidity and high mortality. It is usually seen in young and newly captive birds and occurs when an immunocompromised host inhales an overwhelming number of spores. Onset of clinical disease is rapid and followed by death within several days. Affected birds may show dyspnea, cyanosis, lethargy, anorexia, polyuria, polydipsia and sudden death. A white mucoid exudate and marked congestion of the lungs and air sacs occur. Numerous, diffusely distributed foci of pneumonic nodules also may be variably present.

Acute aspergillosis has been reported to occur in psittacine chicks.<sup>116</sup> Most are septicemic and acutely depressed when illness is observed. In addition to tachypnea, dyspnea and vomiting, abdominal enlargement due to ascites formation frequently develops. The disease is rapidly fatal with few chicks surviving long enough to develop pulmonary granulomas.

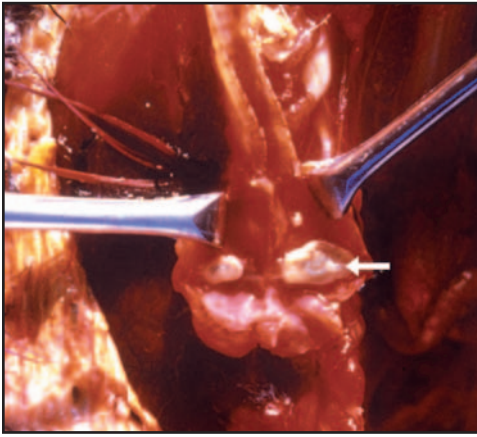
## Mycotic Tracheitis

Mycotic tracheitis refers to a form of aspergillosis localized in the trachea, syrinx and major bronchi.<sup>59</sup> The pathogenesis is similar to that for acute aspergillosis in an immune-compromised host with exposure to numerous fungal spores. Colonization may occur anywhere along the length of the trachea, but is most often found at the level of the syrinx and tracheal bifurcation (Fig 29.3).<sup>87</sup> Granuloma formation causes a progressive course of life-threatening obstructive airway disease (Fig 29.4). A change in vocalization may be present and is highly suggestive of lesions in the syrinx.<sup>87</sup> Birds also may present with a rapid onset of severe dyspnea, open-mouthed breathing, gurgling respirations or a cough.<sup>45,121</sup> Sudden death also may occur.

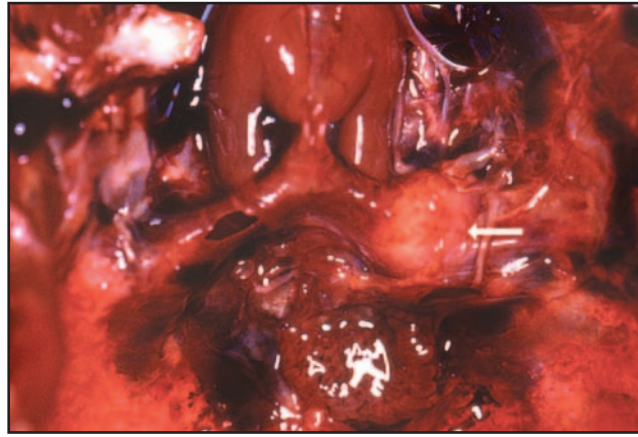
## Chronic Disease

Chronic aspergillosis is the more commonly observed form of the disease. It generally occurs in older birds that have been in captivity and is the result of long-term malnutrition and stress.<sup>8,59</sup> Previous disease, prolonged antibiotic or corticosteroid therapy and other stress factors are contributory. Some form of immunosuppression is implicated in the chronic disease.<sup>95</sup> This form is often seen in species like the African grey parrot, pionus parrot and Amazon parrot.

Chronic forms of the disease can be quite subtle in onset, and early clinical signs are often non-specific. A change in behavior, reduced level of activity and decreased appetite may be observed. In some instances, exercise intolerance and weight loss, even in light of a good appetite, are the only signs noticed.<sup>73</sup> Birds with



**Fig 29.3** | Granuloma (arrow) of the syrinx in a blue-headed pionus parrot (*Pionus menstruus*). The owner noted a characteristic change and weakness in vocalizations several days prior to finding the bird deceased.



**Fig 29.4** | *Aspergillus* granuloma (arrow) occluding the left bronchus in an African grey parrot (*Psittacus erithacus*).

lower respiratory tract involvement may exhibit variable respiratory compromise, depending upon the nature and extent of the lesions present.<sup>53</sup> With the exception of the acute form and mycotic tracheitis, lower respiratory tract aspergillosis is often inapparent. Respiratory signs are usually absent until the disease is extensively developed.<sup>87</sup> Tachypnea and dyspnea are not commonly observed until late in the disease process.<sup>59</sup>

Hepatic signs (biliverdinuria and hepatomegaly) and renal signs (polyuria, polydipsia and renomegaly) may be present. Ascites also may occur. Gastrointestinal involvement (regurgitation, diarrhea and abnormal droppings) is less frequently observed.

*Aspergillus* air sacculitis is the most frequently encountered form of the disease with extension to the lungs commonly occurring.<sup>87</sup> Aspergillomas may be found throughout the entire respiratory tract but most commonly occur in the posterior thoracic and abdominal air sacs (Figs 29.5, 29.6). In advanced cases, changes occur in the respiratory rate and effort and in vocalization. Dyspnea and tachypnea in an unstressed bird, tail bobbing, open-mouthed breathing and audible respiratory sounds are indications of advanced lower respiratory tract disease.<sup>24,59,87,112</sup> Although auscultation is less valuable in avian patients than in mammals for evaluation of respiratory tract disease, abnormal crackles or clicking noises can indicate air sac involvement.<sup>24</sup>

The time from onset of clinical signs to death ranges from less than 1 week to over 6 weeks.<sup>73</sup> *Aspergillus* hyphae are tissue- and angio-invasive and can cause respiratory hemorrhage and acute death in affected birds at any stage of the disease process (Fig 29.7).

Localized aspergillosis involving the upper respiratory

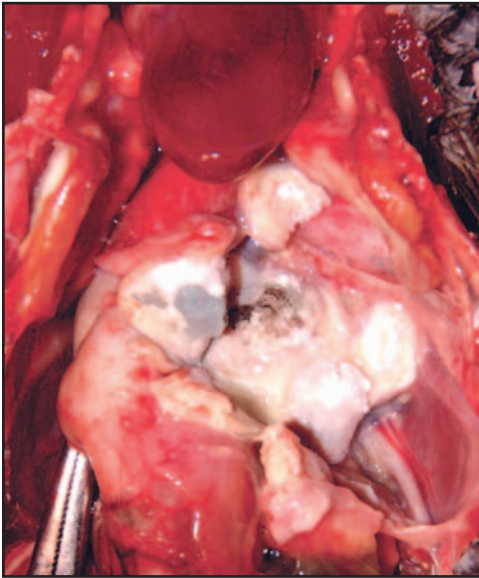
tract often presents as a chronic rhinitis and sinusitis in psittacine birds. Distension of the infraorbital sinus and periorbital soft tissue swellings may be present. Birds may exhibit a unilateral or bilateral nasal discharge that can be serous to purulent in character.<sup>87</sup> Formation of rhinoliths and oronasal granulomas may occur and often obstruct the upper airways, causing wheezing respiratory sounds. Secondary bacterial sinus infections are common. In psittacines, obstruction of the connection between the right and left nares may occur with *Aspergillus* rhinitis. This obstruction may be due to the presence of caseated debris or bony deformation from chronic infection.

### Central Nervous System

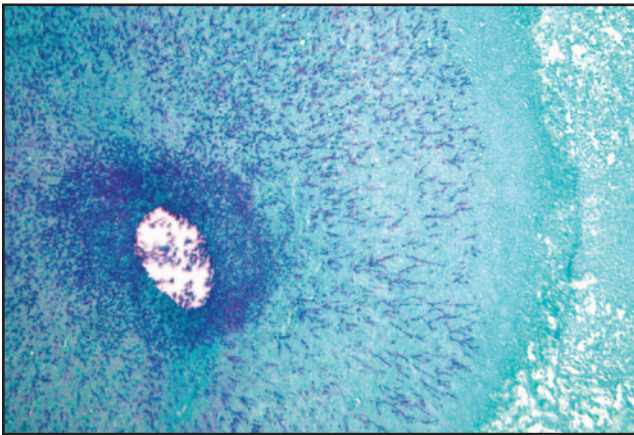
Encephalitic and meningoencephalitic lesions may occur with disseminated aspergillosis. Necrotizing aspergillosis with dissemination of thrombi to the brain and spinal cord is often associated with ataxia or paralysis, incoordination, tremors and torticollis.<sup>73,95</sup> A trumpeter swan (*Cygnus buccinator*) with ataxia, incoordination and heart murmur had cerebral aspergillomas and *Aspergillus* granulomas in both ventricles of the heart.<sup>5</sup>

### Ocular Mycoses

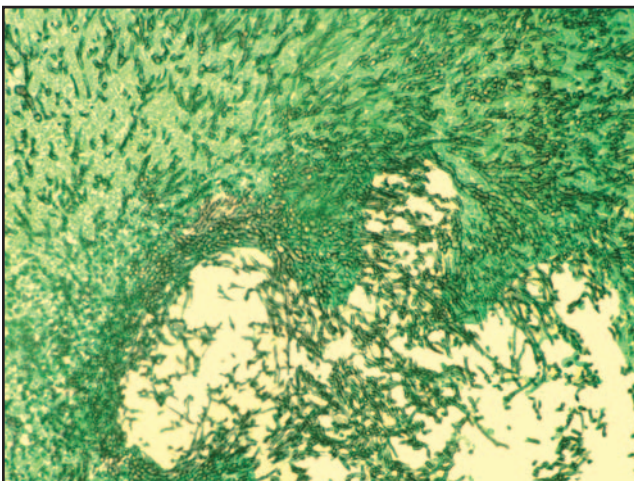
Fungal infections of the eye are rare in birds but have been reported in numerous species.<sup>22,56</sup> *Aspergillus fumigatus* was isolated on conjunctival culture from a blue-fronted Amazon parrot (*Amazona aestiva*) with mycotic keratitis.<sup>56</sup> It was implicated as a cause of severe blepharitis and dermatitis of the eyelids in a falcon/gyrfalcon hybrid (*Falco peregrinus* X *Falco rusticolus*) and keratitis in chickens.<sup>1,10</sup> Most reported occurrences result from the extension of preexisting upper respiratory infections, although ocular trauma and corticosteroid therapy



**Fig 29.5** | *Aspergillus fumigatus* granuloma exhibiting conidiophore growth in the lung and air sacs of an African grey parrot (*Psittacus erithacus*).



**Fig 29.6** | Fungal granuloma in avian lung tissue, central area of necrosis with fungal hyphae. PAS fungal stain.



**Fig 29.7** | Mycelial growth of *Aspergillus fumigatus* throughout an avian pulmonary granuloma. PAS fungal stain.

are other predisposing factors.<sup>10,56,64</sup> Affected birds may show blepharospasm, photophobia, severe periorbital swelling and conjunctival hyperemia.<sup>22,56</sup> Corneal epithelial erosions and stromal necrosis may result in perforation of the cornea or panophthalmitis, resulting in functional loss of the eye.<sup>56</sup> Characteristic signs with recent stress and/or poor nutrition should make aspergillosis a strong presumptive diagnosis.

## ASPERGILLUS DIAGNOSIS

Antemortem diagnosis of aspergillosis is challenging and often requires several diagnostic methods.<sup>15,79</sup> A presumptive diagnosis is often based upon the clinical history, physical exam, clinical impression, complete blood count, radiography and endoscopy. History of a previous stressful event, an immunosuppressive disease or treatment and/or exposure to spore-laden environments is supportive. Clinical signs, especially dyspnea, weight loss, exercise intolerance and chronic debilitation, also suggest aspergillosis; however, a definitive diagnosis requires confirmation of the organism by cytology, culture, histopathology or DNA testing.<sup>8,15,59</sup> Demonstration of the causal agent consistent with the clinical disease and observed lesion(s) is the diagnostic goal.

### Hematology and Serum Chemistry

Aspergillosis generally causes a significant heterophilic leukocytosis (25,000 cells/ $\mu$ l to 100,000 cells/ $\mu$ l), which may be associated with both acute and chronic disease.<sup>15,18</sup> White blood cells are often very reactive and a left shift may be present. Heterophils often exhibit degranulation and other toxic signs. Reactive lymphocyte changes also occur and may result in a marked lymphopenia, especially in Amazon parrot species.<sup>44</sup> A monocytosis is often observed in chronic forms of the disease.<sup>19</sup>

A non-regenerative anemia due to the chronic inflammation of the disease is often present. Lack of an appropriate bone marrow response may be evidenced by the absence of polychromasia, reticulocytosis, macrocytosis and/or anisocytosis.<sup>60</sup> Psittacosis and mycobacteriosis can induce similar hemograms.

Serum biochemistry analysis may show an increase in aspartate aminotransferase (AST), lactate dehydrogenase (LDH) and serum bile acids if liver involvement is present. Hypoalbuminemia and hypergammaglobulinemia also are characteristic of the disease.<sup>87</sup>

Plasma protein electrophoresis may help support the diagnosis of aspergillosis in psittacine birds but is not specific for this disease. Observed changes in the plasma protein electrophoretograms are indicative only of a non-specific inflammatory response.

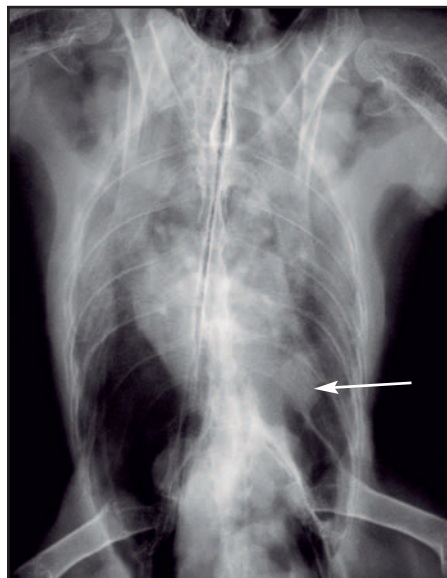
In one study, most (6/7) birds exhibited moderate to marked decrease in the plasma albumin to globulin ratio.<sup>58</sup> Some (3/7) birds showed a moderate to marked increase in  $\beta$ -globulin concentrations. Affected birds may, however, demonstrate normal values for these indices.

### Serology

*Aspergillus* antibody titers have only a moderate predictive value in disease diagnosis. The indirect ELISA assay (The Raptor Center, University of Minnesota) measures *Aspergillus* antibody levels and has shown useful correlation with clinical infections in raptor species, although false-negative results can occur.<sup>95</sup> The test requires species-specific antibody conjugates and is most useful in these species. In a report of falconiform birds with confirmed aspergillosis, 43% (10/23) of the birds had moderate to marked antibody titers, whereas 22% (5/23) had negative titers.<sup>95</sup> In contrast, all 112 owls described in the same report had negative antibody titers despite confirmed aspergillosis in some of these birds. In a study of captive penguins (*Spheniscus humboldti*, *Spheniscus magellanicus*, *Pygoscelis adeliae*) with confirmed aspergillosis, many birds had markedly increased titers and only 20% had negative antibody titers.<sup>96</sup>

A negative antibody titer in an infected bird may be explained either by a lack of reactivity between the test conjugate and patient immunoglobulins or by a lack of patient humoral response (immunosuppression). Lack of humoral response also has been attributed to sequestration of the infection site.<sup>26</sup> In raptors, indirect ELISA values in the mid to high range help confirm the diagnosis when aspergillosis diagnosis correlates with the clinical signs shown by the patient.<sup>93</sup> A positive result means active infection, long-term exposure or previous infection antibody.<sup>95</sup> The test should be utilized with hematology, endoscopy, radiology, and tracheal or air sac culture in potential aspergillosis cases. With treatment, the antibody titer generally rises, and with successful treatment then falls to undetectable levels. Failure of the titer to rise or subsequently drop with treatment is a poor prognostic sign.<sup>15</sup>

*Aspergillus* antibody testing is probably less useful in psittacine species. In a report documenting the sensitivity of serologic testing in detecting aspergillosis in psittacine birds, *Aspergillus* antibody and antigen ELISA titers in infected birds were weakly positive.<sup>58</sup> The incidence of weakly positive antigen titers in clinically normal birds is reported to be high, making these results difficult to interpret clinically.<sup>26,58</sup> Currently, there is no hematologic test that can reliably detect aspergillosis in psittacine birds.<sup>58</sup>

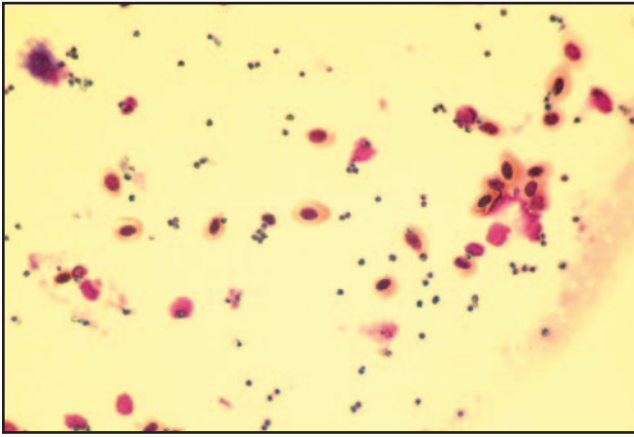


**Fig 29.8** | Radiograph of an *Aspergillus* granuloma (arrow) in the air sac of a blue and gold macaw (*Ara ararauna*).


### Radiology

Radiographic evaluation can demonstrate the distribution and severity of mycotic lesions in the lungs and air sacs but is usually of limited diagnostic value until late in the disease process. Although mycotic air sacculitis with granuloma formation is well documented in a variety of avian species, lesions are usually advanced before becoming radiographically apparent.<sup>24,87,112</sup> A bronchopneumonia with marked parabronchial patterns is one of the more common radiologic findings.<sup>73</sup> The fibrinous air sacculitis associated with aspergillosis allows for radiographic visualization of the air sac walls.<sup>87</sup> Asymmetry, hyperinflation or consolidation of the air sacs may be evident. A nodular air sacculitis with focal air sac densities is often seen and occurs primarily in the abdominal and, less often, thoracic air sacs. Single or multiple soft tissue densities in the air sacs or lungs are most often granulomas but should be considered non-specific (Fig 29.8).<sup>73</sup> Although intraluminal granulomas of the syrinx, trachea and main stem bronchi are fairly common, they are seldom visualized radiographically. The syrinx is often obscured by soft tissue and bone.<sup>87</sup> Fungal air sacculitis usually causes plaque-like and nodular granulomatous lesions in the air sacs. Even after the successful resolution of clinical *Aspergillus* infection, lungs and air sacs may remain thickened and irregular and appear abnormal both radiographically and via endoscopic examination.

Computed tomography (CT) scans provide a detailed image of all parts of the respiratory tract and are useful for demonstrating small lesions that are not visible on radiographs and for visualizing lesions in the infraorbital sinus, retrobulbar area, trachea and main stem bronchi.<sup>87</sup>



**Fig 29.9** | *Aspergillus* spores and avian red blood cells from a clinical sample obtained during diagnostic endoscopy.



**Fig 29.10** | Hyphal elements and spores of *Aspergillus fumigatus* in Gram's-stained clinical specimen collected at endoscopy.

A concurrent hepatomegaly and renomegaly may be visualized on radiography or detected by abdominal palpation.<sup>99</sup>

### Endoscopy

Air sac consolidation and granulomas can obscure radiographic detail in the coelomic cavity. Lesions are often best observed by endoscopy, which is an efficient way to detect and sample fungal plaques in the trachea, syrinx or lower respiratory tract.<sup>94,109</sup>

The trachea (depending on species and the size of scope being used) can be visualized down to the level of the syrinx with both rigid and flexible endoscopes. Depending on the extent of the disease and chronicity of the condition, air sacs that are normally thin and transparent may be thickened, cloudy or covered with exudate. Early in the disease process, prominent vascularity of the air sacs may be the only observable abnormality.<sup>95</sup> Fungal air sacculitis usually causes plaque-like, coalescing and nodular granulomatous lesions in the air sacs. Plaques vary from white to yellow in color to green to black on the surface, owing to the development of conidia and fungal spores.<sup>97</sup> The observation of typical lesions by endoscopy with biopsy sample collection for cytology, histopathology or fungal culture can provide a confirmed diagnosis of aspergillosis. Endoscopy is useful in evaluating the extent of infection and monitoring progress during treatment<sup>94</sup> (see Chapter 1, Clinical Practice and Chapter 24, Diagnostic Value of Endoscopy and Biopsy).

### Cytological Evaluation

Cytologic evaluation of clinical samples can aid the diagnosis of aspergillosis. Choanal swabs, infraorbital sinus aspirates, tracheal and air sac swabs and washings may reveal *Aspergillus* hyphae and spores (Fig 29.9).<sup>8</sup> Squash preparations of wet mount clinical specimens are prepared and stained with lactophenol cotton blue or meth-

ylene blue stain.<sup>95</sup> Microscopic evaluation often reveals long, dichotomously branched ( $\sim 45^\circ$ ), septate hyphae, 2.5 to 4.5  $\mu\text{m}$  in diameter. Fruiting bodies with spores also may be identified (Fig 29.10).

### Confirming the Diagnosis

Histopathology and fungal culture can be used to demonstrate the organism in clinical samples and are important in providing a confirmed diagnosis of the disease. DNA probe testing of clinical specimens also can validate the diagnosis. Tracheal swabs or air sac swabs and granuloma biopsy specimens obtained at endoscopy can be tested specifically for *A. fumigatus*.<sup>3</sup> Genus-specific probes can be used to test for *Aspergillus* spp. in general. Research on the use of DNA probe testing of whole blood samples suggests that this may be helpful in providing a confirmed diagnosis of the disease.

## TREATMENT

### Amphotericin B

Amphotericin B<sup>b</sup> is an amphoteric polyene macrolide anti-fungal agent.<sup>72</sup> Its mechanism of action is to bind ergosterol, the principal sterol present in the cell membrane of sensitive fungi.<sup>65</sup> It has a wide spectrum of activity, being fungicidal to both *Aspergillus* spp. and *Candida* spp., and to other fungi including *Blastomyces*, *Coccidioides*, *Histoplasma*, *Sporothrix* and *Mucor* spp.

Amphotericin B<sup>b</sup> has been used to treat both systemic and topical fungal infections in birds.<sup>38</sup> It can be administered intratracheally, intravenously, in sinus flushes and through nebulization. Parenteral use quickly establishes fungicidal concentrations, making it a frequent choice for initial therapy. The drug is eliminated by the kidneys and is used for only short duration due to the risk of induced nephrotoxicity. A dose of 1.5 mg/kg IV is administered q8h for a period of 3 to 5 days and in combination with

itraconazole<sup>c</sup>, fluconazole<sup>d</sup> or terbinafine<sup>f</sup> orally.<sup>38</sup> Combined nebulization therapy with clotrimazole<sup>e</sup> or terbinafine also is suggested (see Chapter 9, Therapeutic Agents).

Sinus and tracheal aspergillosis are more difficult to treat. Intratracheal use of amphotericin B<sup>b</sup> at 1 mg/kg q8-12 h has been described as supplemental treatment for these infections. Topically, the drug can be very tissue irritating and must be diluted in water (saline inactivates amphotericin B<sup>b</sup>) to reduce the risk of iatrogenic sinusitis or tracheitis.<sup>59</sup> Nebulization with amphotericin B<sup>b</sup> has been reported to cause severe bronchoconstriction in horses.<sup>13</sup> Amphotericin B<sup>b</sup> has been used in nebulization and sinus flushes for 20 years in avian species with good success and no clinical complications.

### Itraconazole

Itraconazole<sup>c</sup> is one of the most widely used antifungal agents in birds and is especially effective in combination with nebulized clotrimazole<sup>e</sup> and/or intravenous amphotericin B<sup>b</sup>.<sup>40,81,95</sup> It has greater efficacy than ketoconazole<sup>i</sup> or fluconazole<sup>d</sup> against *Aspergillus* spp. and has less potential toxicity than amphotericin B<sup>b</sup>.<sup>47,95,115</sup> It has been used effectively to treat aspergillosis in raptors, psittacine birds and waterfowl, and is a recommended treatment of choice in these species.<sup>38,40,81,95</sup>

Itraconazole<sup>c</sup> is eliminated by hepatic metabolism and is generally well tolerated during long-term use.<sup>83</sup> The effective drug dose and potential for adverse effects is variable among avian species. In most psittacine species, effective serum concentrations are attained when therapy is initiated at 5 to 10 mg/kg PO twice daily for 5 days, then once daily for the duration of treatment.<sup>82,87</sup> Temporary anorexia and lethargy were the only side effects observed in an orange-winged Amazon parrot (*Amazona amazonica*) treated with 5 mg/kg itraconazole<sup>c</sup> for 1 year.<sup>83</sup> African grey parrots are reportedly more sensitive to itraconazole<sup>c</sup> and may exhibit adverse drug effects at normal dosage levels. One report suggests that the drug may have contributed to several deaths in this species.<sup>83</sup> A dose of 2.5 to 5.0 mg/kg PO q24h is recommended for use in African grey parrots.<sup>87</sup>

Itraconazole<sup>c</sup> is safe in raptors when dosed at 10 mg/kg per day PO for 3 to 6 months duration.<sup>61</sup> Hawks treated at this level reached steady state plasma levels within 2 weeks, with effective organ tissue levels adequate to treat most fungal infections.<sup>61</sup> Poor distribution in the respiratory tissues after oral dosing in pigeons has been reported, which might limit applicability in this species.<sup>70</sup> A dose of 6 mg/kg q12h in pigeons achieves effective plasma concentrations; however, a comparatively higher dose of 26 mg/kg PO q12h is needed to attain effective

respiratory tissue levels.<sup>70</sup>

Itraconazole<sup>c</sup> is marketed as capsules containing coated lactose granules, which are soluble only at low pH. Dissolution of these granules in acid solutions results in improved bioavailability and higher blood itraconazole<sup>c</sup> levels following oral administration in avian patients.<sup>61,83</sup> Absorption also is enhanced when the drug is administered with a fatty meal.<sup>82</sup> It is recommended that itraconazole<sup>c</sup> beads from a 100-mg capsule be divided into five equal parts of 20 mg each. Each 20-mg aliquot is dissolved in 0.4 ml of 0.1 N HCl. The resulting solution is diluted to a final concentration of 5 mg/ml by the addition of orange juice.<sup>61</sup> For avian dosing, the drug is administered by gavage with food. Itraconazole<sup>c</sup> also is available in a 10 mg/ml liquid<sup>c</sup> for oral administration that avoids any concern with sufficient dissolution or suspension.

### Other Agents

Fluconazole<sup>d</sup> is effective against aspergillosis although generally less so than itraconazole<sup>c</sup>. It is rapidly absorbed with high bioavailability after oral administration. The drug is widely distributed to the extracellular space, making it useful for treating mycoses of the eye and central nervous system.<sup>71</sup> *Aspergillus* keratomycosis in a blue-fronted Amazon parrot was treated with oral and topical fluconazole<sup>d</sup>.<sup>56</sup> A dose of 5 to 15 mg/kg PO q12h is recommended in most psittacine species.<sup>21</sup>

Clotrimazole<sup>e</sup> and enilconazole<sup>k</sup> are relatively insoluble and useful against aspergillosis only at sites that can be treated topically with the drug or reached by inhalation or nebulization. Miconazole<sup>l</sup> is effective for treating fungal keratoconjunctivitis when used in an ophthalmic form with frequent medication intervals (q3-4h).<sup>4,14,41,56</sup>

Terbinafine hydrochloride<sup>f</sup> is a synthetic allylamine antifungal agent that is fungicidal against a wide variety of dermatophytes, molds and fungi. The drug's efficacy is similar to or more effective than amphotericin B<sup>b</sup> and itraconazole<sup>c</sup> against *Aspergillus* spp., and has been used to treat aspergillosis effectively in psittacine species.<sup>28</sup> In addition to its fungicidal property, terbinafine<sup>f</sup> has good ability to penetrate mycotic granulomas. It is readily absorbed after oral administration and has a low potential for adverse side effects. No signs of toxicosis were observed during prolonged drug administration in psittacine birds.<sup>28</sup> The drug has proven very useful as an alternative treatment for avian aspergillosis, especially in cases where more conventional therapies have been ineffective. The combination therapy of terbinafine<sup>f</sup> at 10 to 15 mg/kg PO q12-24h with itraconazole<sup>c</sup> is a safe and very effective treatment for systemic avian fungal disease.



## Nebulization Therapy

Aerosolization therapy is used to augment systemic treatment by delivering drugs directly to the respiratory tract. Target tissues receive high concentrations of the drug while minimizing systemic exposure.<sup>15</sup> In addition, hepatic first-pass metabolism following oral administration is circumvented.<sup>15</sup> Clotrimazole<sup>c</sup> supplied as a 1% solution can be used for nebulization therapy at 30 minutes q24h.<sup>63</sup> However, a 15% aqueous suspension can be compounded, which appears to be more effective than the commercial form (P. Redig, personal communication, 2003). Terbinafine hydrochloride<sup>f</sup> nebulized as a 1 mg/ml aqueous solution (20 minutes q8h) was effective in resolving a non-responsive respiratory aspergillosis in a 6-year-old Congo African grey parrot (*Psittacus erithacus*).<sup>28</sup>

A commercially available disinfectant<sup>g</sup> is useful for treatment of birds within their quarters or en masse when nebulized at a 1:250 aqueous dilution. Nebulization therapy q12h for 3 to 12 weeks has been successful in the treatment of aspergillosis in a 12-week-old Congo African grey parrot and effective in combination with itraconazole<sup>c</sup> for raptorial species.<sup>7,107</sup> It also can be used to fog aviary rooms and pigeon lofts to reduce the level of fungal contamination in these premises<sup>107</sup>.

## Surgical Treatment

Treatment of respiratory aspergillosis is clinically challenging. Granulomatous lesions may occlude vital respiratory pathways or prove resistant to therapy because of poor drug penetration into the encapsulated lesions.<sup>24,87,112</sup> If nebulization and systemic administration of antifungal agents is not effective, surgical debulking of granulomas may be necessary.<sup>87</sup> For infections of the sinus cavities, trephination of the frontal sinuses permits direct access to granulomas for debridement and topical application of medications in an otherwise inaccessible site.<sup>87</sup>

Rhinitis or sinusitis of *Aspergillus* origin may require enzymatic therapy to dissolve the caseated debris and allow flushing of the affected area with the appropriate antifungal agent. Both hyaluronidase and trypsin-based flushes have been used for this purpose.

Tracheal and syringeal granulomas may precipitate life-threatening respiratory tract obstructions. Granulomas often form just proximal to or at the bifurcation of the trachea. Birds can effectively ventilate through cannulae placed in the clavicular, caudal thoracic or abdominal air sacs.<sup>33,51,98,101</sup> These can provide an alternative airway in emergency cases of tracheal obstruction and can be used for both short- and long-term duration. They can be left in place for periods of up to 1 week, but should be removed when possible to prevent iatrogenically induced air sacculitis.<sup>89,101</sup>

Cannulae also may be used to induce and maintain anesthesia during tracheal, syringeal or oral surgery. For suspected tracheal granulomas, an open-end tom cat catheter can be used to obtain clinical samples and for suction therapy to cannulate the tracheal lumen. Tracheotomy, through a ventral midline incision centered over the thoracic inlet, may be used to access granulomas in the tracheal lumen.<sup>30,89</sup> If the granuloma is at the level of the syrinx, blunt dissection through the interclavicular air sac or an alternative left lateral approach may provide needed access.<sup>89</sup> A clavicular osteotomy may be necessary to improve surgical access to the syrinx in some birds.<sup>89</sup>

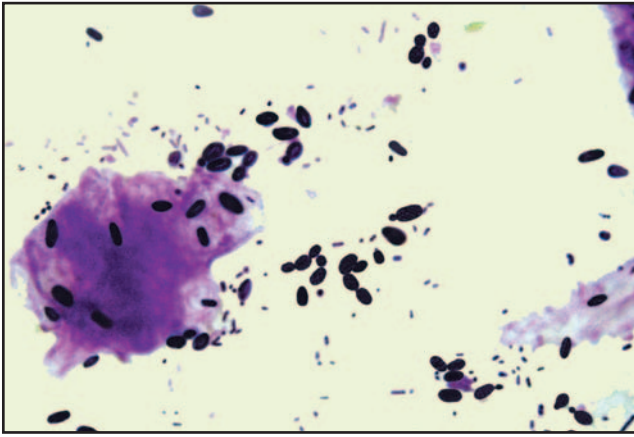
Fungal granulomas of the lower respiratory tract are often resistant to medical therapy.<sup>24,87,112</sup> Surgical resection of these masses has been recommended; however, little has been published about techniques and their respective success.<sup>24,89,109</sup> Attempts at surgical removal are often incomplete due to the location of granulomas within the respiratory tract and the need to minimize trauma to adjacent structures.<sup>53</sup> Endoscopy allows access to most of the lower avian respiratory tract with minimal trauma and is an alternate approach for removing these lesions.<sup>109</sup> A detailed knowledge of the avian air sac system and competence with the rigid endoscope is a prerequisite before attempting this procedure<sup>53</sup> (see chapter 24, Diagnostic Value of Endoscopy and Biopsy).

A recent report describes endoscopic debridement and laser ablation as a viable alternative to conventional surgery in the management of lung and air sac granulomas.<sup>53</sup> A gallium-aluminum-arsenide diode laser, employing flexible fibers passed through the operating channel of the rigid endoscope, was used to ablate remaining granulomatous tissues in the air sacs after endosurgical debulking.<sup>53</sup> A small volume of amphotericin B<sup>b</sup> was used to sterilize the remaining lesion. Greater clinical success was achieved by endosurgical debridement and laser ablation, compared with conventional surgical exploration and removal of granulomas or medical therapy alone.<sup>53</sup>

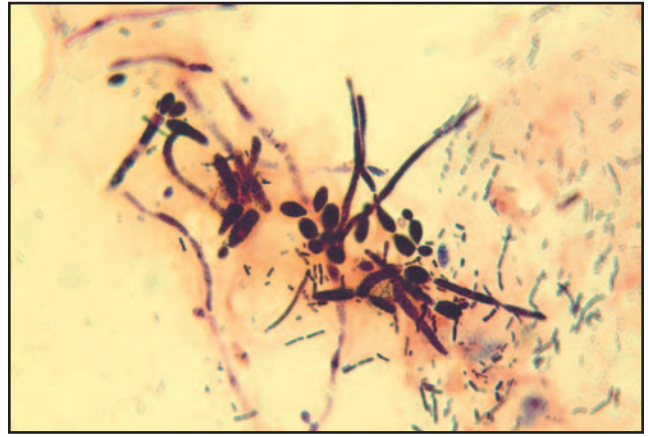
## Summary

In treating aspergillosis, proper supportive care including heated environment, fluids and nutritional support are essential. Because affected birds are severely compromised, the risk of secondary bacterial infections is significant. Antibiotic therapy is indicated. Prolonged antifungal therapy for periods up to 4 to 6 months is often necessary for treatment success.

Patients should be closely monitored for clinical improvement and observed for any signs of toxicosis during this period. Treatments are usually continued for 1 month after the complete blood count has returned to normal.<sup>87</sup> Aspergillosis is a preventable disease. Proper



**Fig 29.11** | *Candida albicans* in an avian fecal Gram's stain. Yeast in this form proliferates in the lumen of the digestive tract and is responsive to topically acting antifungal agents (nystatin<sup>h</sup>).



**Fig 29.12** | *Candida albicans* exhibiting mycelial growth in a fecal Gram's stain from a cockatiel (*Nymphicus hollandicus*). Yeast in this form is tissue invasive and requires systemic antifungal therapy for proper treatment.

diet and husbandry practices to reduce stress and provide good hygiene will reduce factors that predispose to the development of this disease.

## Candidiasis

Candidiasis in birds, also known as thrush, moniliasis or sour crop, refers to infections by yeasts of the genus *Candida*. *C. albicans* is the most commonly implicated species, although *C. parapsilosis*, *C. krusei*, and *C. tropicalis* also may cause disease.<sup>103</sup>

*C. albicans* is an opportunistic yeast and not regarded as a primary pathogen. Small numbers of the non-budding organism are commonly found in the digestive tract of normal birds and considered normal flora in healthy pigeons.<sup>102</sup> Host defense mechanisms and bacterial flora keep numbers of the organism controlled. *Candida* spp. can proliferate and cause disease when digestive tract flora are severely suppressed. In most cases, the infection is endogenous in origin, occurring secondarily to stress, immunosuppression, inadequate nutrition, poor sanitation, debilitation or in birds that have been extensively treated with antibiotics.

This disease is most often seen in psittacine neonates and cockatiels. Yeasts gain entry into the host by the oral route.<sup>102</sup> The organisms can be transmitted from the parent bird to chicks during regurgitative feeding. The infection also may be spread throughout the nursery population by the use of contaminated fomites and feeding utensils.

Candidiasis affects the mucocutaneous areas of the body and gastrointestinal mucosa, particularly of the oropharynx, crop and esophagus. Affected birds are depressed and may exhibit delayed crop emptying, regurgitation,

crop stasis, inappetence and poor digestion of food. Droppings are often abnormal, appearing brownish in color and watery. Affected chicks do not grow or gain weight well and appear stunted.

Lesions vary in severity. They consist of thickening of the digestive tract mucosa with increased mucous and pseudomembranous patches. The choanae may become abscessed with formation of a diphtheritic membrane in the oropharynx as mycelial growth develops.<sup>102</sup> Whitish plaques may be evident under the tongue, in the mouth and most frequently in the crop. In advanced cases, stomatitis and palpable thickening of the ingluvies are present. Endoscopic examination of affected membranes of the oropharynx, crop, esophagus, proventriculus and ventriculus may reveal white-grey to grey-green, thickened and diphtheritic membranes. A characteristic "Turkish towel" thickening of the crop lining is evident in advanced cases.

Diagnosis is made by identifying the organism on wet or Gram's-stained smears from lesions in the oral cavity, crop or cloaca (Fig 29.11). Crop washings and fecal samples also may be used. *Candida albicans* grows as a budding yeast cell, oval in shape, 3.5 to 6.0 x 6.0 to 10.0  $\mu\text{m}$  in size. High numbers of budding yeast confirm the diagnosis. The presence of elongated pseudohyphae suggests more severe infection with deeper tissue involvement (Fig 29.12). The organism can be cultured on mycological agar with cycloheximide and chloramphenicol at 37° C for 24 to 48 hours. Growth appears as shiny and convex round colonies measuring 3 to 5 mm in diameter, pearl white to light cream in color.

Differential diagnoses for inflammation of the upper gastrointestinal tract include bacterial stomatitis, trichomoniasis, capillariasis and nutritional disorders (see Chapter 4, Nutritional Considerations).

## TREATMENT

Correction of the diet and husbandry are necessary for successful treatment of candidiasis. Nystatin<sup>h</sup> is the first drug of choice for yeast infections confined to the alimentary tract. It is not absorbed from the digestive tract and is effective for oral or topical use only. Nystatin<sup>h</sup> is fungistatic in action and must come in contact with the organism to be effective. Oral lesions may not respond if the drug is administered by gavage tube beyond this site of infection. The drug also can be applied directly to lesions of the mucous membranes in the oropharynx. The recommended dose of 290,000 units/kg PO q8-12h is safe and effective for use in psittacine neonates.<sup>21</sup> For flock treatment, nystatin<sup>h</sup> can be added to the drinking water at 100,000 IU/L.<sup>102</sup>

Severe yeast infections may be refractory to nystatin<sup>h</sup> therapy. If the organism is resistant to nystatin<sup>h</sup> or is in the hyphal stage, having penetrated the wall of the digestive tract, systemic antifungals are indicated. Fluconazole<sup>d</sup> or ketoconazole<sup>i</sup> are the systemic drugs of choice. Fluconazole<sup>d</sup> is one of the most effective antifungal agents for the treatment of tissue-based yeast infections. A dose of 5 to 15 mg/kg PO q12h is recommended for most avian species.<sup>21</sup> It also is effective against alimentary tract yeast when added to the drinking water at 50 mg/L.<sup>102</sup> Ketoconazole<sup>i</sup> also can be used to treat systemic yeast infections at 10 to 30 mg/kg PO q12h. It can be added to the drinking water at 200 mg/L for flock treatment of pigeons.<sup>102</sup>

Itraconazole<sup>c</sup> has been used in the successful treatment of candidal tracheitis in a blue and gold macaw (*Ara ararauna*) and candidal infection of the uropygial gland in a king penguin (*Aptenodytes patagonicus*).<sup>55</sup> Some *Candida* spp. are, however, extremely resistant to itraconazole.<sup>114</sup> The drug is unlikely to achieve therapeutic concentrations at 5 mg/kg and should be used at the higher dose of 10 mg/kg PO q24h.

Oral chlorhexidine<sup>j</sup> at 10 to 20 ml per gallon drinking water for 3 weeks can be used for flock control of *Candida* infections but generally will not eliminate them. Mild cases of candidiasis may respond to acidification (see apple cider vinegar in Chapter 9, Therapeutic Agents).

## Macrorhabdosis

Clinical disease caused by the organism historically known as *Megabacterium* has been referred to as megabacteriosis, *Megabacterium*-associated disease and proventricular disease in birds.<sup>6,36</sup> More recent studies have confirmed that the organism is a fungus and repre-

sents a new genus of ascomycetous yeast called *Macrorhabdus ornithogaster*.<sup>91,110</sup> The clinical condition in birds is more properly referred to as macrorhabdosis. The reader is referred to Chapter 30, Implications of *Macrorhabdus* in Clinical Disorders in this text for detailed discussion on this topic.

## Mycotic Dermatitis

Fungal dermatitis is rarely reported in birds, even though fungi such as *Trichophyton* and *Aspergillus* spp. have been recovered from the feathers, skin and eyes of healthy birds.<sup>32,122</sup> Infections of the integument caused by *Candida albicans*, *Rhodotorula*, *Microsporum gallinae*, *Aspergillus*, *Rhizopus*, *Malassezia* and *Mucor* species have been described.<sup>17,25,85,118</sup> Skin and feather lesions associated with *Aspergillus* have been recognized in pigeons and psittacine birds.<sup>111</sup> *Aspergillus* and *Alternaria* spp. also have been associated with epidermal cysts in the domestic chicken.<sup>108</sup> Other reports of fungal dermatitis include *Trichophyton* in canaries (*Serinus canarius*), *Microsporum gypseum* in budgerigars (*Melopsittacus undulatus*), *Microsporum gallinae* and *Cladosporium berbarum* in chickens (*Gallus gallus*) and *Candida* species in gallinaceous birds.<sup>66,105,111</sup>

Favus, commonly referred to as “avian ringworm,” describes a mycotic dermatitis found primarily in gallinaceous birds. It consists of white, crusting lesions of the face, comb and wattles that can extend to the feathered portion of the head. *Microsporum gallinae* is the agent most often involved, although *M. gypseum* and *Trichophyton simii* also have been isolated.

Correction of diet and husbandry issues combined with topical and oral systemic miconazole<sup>l</sup> therapy is usually efficacious in treating mycotic dermatitis in affected birds.

## Cryptococcosis

Cryptococcosis is most commonly caused by infection with *Cryptococcus neoformans* var. *neoformans*, an encapsulated saprophytic fungus with worldwide distribution. *Cryptococcus neoformans* var. *gatti* is more geographically restricted because of an ecological association with the river red gum (*Eucalyptus camaldulensis*) and other eucalyptus trees.<sup>34</sup> The organism is commonly found in soils contaminated with bird droppings.<sup>68</sup>

While cryptococcosis is a rare disease of birds, disseminated infection has been reported in the green-winged macaw (*Ara chloroptera*), Moluccan cockatoo (*Cacatua*

*moluccensis*), thick-billed parrot (*Rhynchopsitta pachyrhyncha*) and North Island brown kiwi (*Apteryx australis mantelli*).<sup>23,27,35,54,100</sup> Infections may involve the respiratory tract, digestive tract and central nervous system, producing necrotic granulomatous lesions and a characteristic thick, pale, gelatinous exudate. The lower temperature of the upper respiratory tract makes it more susceptible than other areas of the body to initial colonization with *Cryptococcus*.<sup>23</sup> Upper respiratory tract involvement can produce facial granulomas that distort the rhamphotheca.<sup>20,27,31</sup> A chronic rhinosinusitis resembling a neoplasm of the rhamphotheca was described in a Major Mitchell's cockatoo (*Cacatua leadbeateri*) and was due to *C. neoformans* var. *gatti*.<sup>90</sup> An encephalitis or meningitis also may occur, causing blindness or paralysis in affected birds.<sup>23,35</sup>

Diagnosis of cryptococcosis should be based on cytology and histopathology in combination with culture rather than culture of nasopharyngeal swabs or washes alone.<sup>90</sup> *Cryptococcus neoformans* var. *neoformans* and var. *gatti* may be carried asymptotically in the upper respiratory tract. Wright's-stained smears of gelatinous material often reveal aggregates of encapsulated yeast organisms measuring 6 to 10  $\mu\text{m}$  within 8- to 12- $\mu\text{m}$  non-staining capsules.<sup>90</sup>

Veterinarians must use extreme caution when handling clinical materials that may contain *Cryptococcus* spores. Most human infections occur through contact with contaminated exudates, fecal material and non-clinical infected or diseased birds.<sup>74,78</sup> While human infection with *C. neoformans* var. *neoformans* is well recognized in immunosuppressed patients, infection with *C. neoformans* var. *gatti* is commonly associated with otherwise healthy and immunocompetent individuals.<sup>68,106</sup>

Antifungal agents such as amphotericin B<sup>b</sup>, fluconazole<sup>d</sup> or itraconazole<sup>c</sup> have been suggested as treatment for cryptococcosis.<sup>23</sup> Fluconazole<sup>d</sup> administered orally at a dosage of 8 mg/kg q24h for 2 months was successful in resolving bilateral nasal cryptococcosis in an African grey parrot, but the lesions recurred 3 years later.<sup>31</sup>

Although cryptococcosis is a rare disease of birds, the zoonotic potential associated with this infection is significant. Veterinarians must be aware of this disease when diagnosing and treating upper respiratory disease in birds and must remember to discuss the zoonotic potential of this infection with their clients.

## Histoplasmosis

Histoplasmosis is an infectious but not contagious mycotic disease that has been reported in poultry and

zoo specimens. The soil-borne organism *Histoplasma capsulatum* has worldwide distribution and is endemic in the eastern and central USA. It is commonly associated with fecal material from pigeons and gallinaceous birds, and has the potential to grow within dirt substrates of enclosed aviaries.<sup>8</sup> *Histoplasma* infections in birds produce disease signs similar to those seen with *Cryptococcus* spp. infections. An initial pneumonia can progress to disseminated disease with the formation of necrotic granulomas. Histoplasmosis was identified as the cause of an osteomyelitis and mineralized soft tissue granuloma of the shoulder and antebrachium in a Moluccan cockatoo.<sup>119</sup> The infection should be considered part of the differential diagnosis of granulomatous respiratory disease in avian patients. Diagnosis is based on culture of the organism and histopathologic examination of tissue samples.

## Mucormycosis

The order Mucorales includes a number of saprophytic fungi that have been implicated as possible avian pathogens. They have been implicated as an etiologic agent of meningoencephalitis in birds.<sup>11,86</sup> Hyphal invasion of cerebral blood vessels and dissemination of an *Absidia* sp. in the cerebrum was identified as the cause of progressive neurologic defects culminating in seizures in a chattering lory (*Lorius garrulus*).<sup>80</sup> Other clinical syndromes described include air sacculitis in a pigeon (*Columba* sp.), pneumonia in a rock hopper penguin (*Eudyptes crestatus*) and a group of rock ptarmigan (*Lagopus mutus*), and an osteolytic mass involving the ribs and air sacs of a penguin (Sphenisciformes).<sup>12,50,67,84</sup> The feeding of damp, germinated seed has been implicated in disseminated mucormycosis causing alimentary granulomas in a group of canaries (*Serinus canarius*) and nephritis in an African grey parrot; glossitis in an African grey parrot; myocarditis in an Australian parakeet (*Psittacula* sp.); and nasal infection in waterfowl.<sup>16,29,75</sup> *Absidia corymbifera* is the pathogen most often isolated, although *Mucor* and *Rhizopus* spp. also are identified.<sup>66</sup>

Antemortem diagnosis of mucormycosis is difficult because the organisms do not culture well from clinical samples.<sup>69</sup> Histopathology of biopsy specimens is more reliable in confirming the diagnosis.<sup>80</sup>

No effective treatment of mucormycosis in birds has been reported. Amphotericin B<sup>b</sup> is the single most reliable agent used in humans.

Other antifungal medications including nystatin<sup>h</sup>, 5-fluorocytosine<sup>m</sup>, clotrimazole<sup>c</sup> and miconazole<sup>l</sup> are reported to have no consistent in vivo activity against the Mucorales.<sup>69</sup>

# Dactylariosis

Dactylariosis is a fatal encephalitis of poultry caused by *Dactylaria gallopava*. The organism grows in old sawdust and wood shavings. Infection involves the central nervous system, causing torticollis, incoordination, tremors and sternal recumbency. The respiratory system is a less commonly involved site. The signs and lesions of dactylariosis resemble those caused by aspergillosis. Culture can be used to differentiate the infection.

## Resources Mentioned in the Text

- a. Veterinary Molecular Diagnostics, Inc, 5989 Meijer Dr, Suite 5, Milford, OH 45150, USA, 513-576-1808
- b. Fungizone, Bristol-Meyers Squibb Company, Princeton, NJ 08543, USA

## References and Suggested Reading

1. Abrams GA, et al: *Aspergillus* blepharitis and dermatitis in a peregrine falcon-gyr Falcon hybrid (*Falco peregrinus* X *Falco rusticolus*). *J Avian Med Surg* 15:114-120, 2001.
2. Ainsworth GC, Austwick PK: *Fungal Diseases of Animals*. Farnham Royal, Slough, England, 1973.
3. Anderson N: Candida/Megabacteria proventriculitis in a lesser sulphur-crested cockatoo (*Cacatua sulphurea sulphurea*). *J Avian Med Surg* 7:197-201, 1993.
4. Andrew SE, et al: Equine ulcerative keratomycosis: Visual outcome and ocular survival in 39 cases (1987-1996). *Equine Vet J* 30:109-116, 1998.
5. Atkinson R: Unusual presentations of aspergillosis in wild birds. *Proc Assoc Avian Vet*, 1998, pp 177-181.
6. Baker JR: Megabacteriosis in exhibition budgerigars. *Vet Rec* 131:12-14, 1992.
7. Bailey T, Sullivan T: Aerosol therapy in birds using a novel disinfectant. *Exotic DVM* 3(4):17, 2001.
8. Bauck L: Mycosis. *In* Ritchie BW, Harrison GJ, Harrison LR (eds): *Avian Medicine: Principles and Application*. Lake Worth, FL, Wingers Publishing, 1994, pp 997-1006.
9. Bauck L, et al: Case reports. *Proc Assoc Avian Vet*, 1992, pp 134-139.
10. Beckman BJ, et al: *Aspergillus fumigatus* keratitis with intraocular invasion in 15-day-old chicks. *Avian Dis* 38:660-665, 1992.
11. Bennett RA: Neurology. *In* Ritchie BW, Harrison GJ, Harrison LR (eds): *Avian Medicine: Principles and Application*. Lake Worth, FL, Wingers Publishing, 1994, pp 723-747.
12. Bigland CH, Graesser FE, Penniford KS: An osteolytic mucormycosis in a penguin. *Avian Dis* 5:367-370, 1961.
13. Boothe DM: Drugs affecting the respiratory system. *Vet Clin No Am Exotic Pet Med* 3:371-394, 2000.
14. Brooks DE, et al: Antimicrobial susceptibility patterns of fungi isolated from horses with ulcerative keratomycosis. *Am J Vet Res* 59:138-142, 1998.
15. Brown PA, Redig, PF: *Aspergillus* ELISA: A tool for detection and management. *Proc Assoc Avian Vet* 1994, pp 295-300.
16. Burr EW, Huchzermeyer FW: Mucormycosis in a parrot. *Mod Vet Pract* 12:961-962, 1982.
17. Burgmann PM: Common psittacine dermatologic diseases. *Sem Avian Exotic Pet Med* 4:169-183, 1995.
18. Campbell TW: *Avian Hematology and Cytology*. Ames, IA, Iowa State Univ Press, 1995, pp 3-19.
19. Campbell TW: *Hematology*. *In* Ritchie BW, Harrison GJ, Harrison LR (eds): *Avian Medicine: Principles and Applications*. Brentwood, TN, HBD Int'l Inc, 1999, pp 177-198.
20. Cannon M: Avian cryptococcosis: A case report. *Proc Aust Comm Assoc Avian Vet*, 1999, pp 1-5.
21. Carpenter JW, Mashima TY, Rupiper DJ: *Exotic Animal Formulary*. Philadelphia, WB Saunders Co, 2001.
22. Carrasco L, et al: Application of enzyme-immunochemistry for the diagnosis of aspergillosis, candidiasis, and zygomycosis in three lovebirds. *Avian Dis* 37:923-927, 1993.
23. Cliphsham R, Brit JO: Disseminated cryptococcosis in a green-winged macaw (*Ara*). *J Am Vet Med Assoc* 183:1303-1304, 1983.
24. Clippinger TL: Diseases of the lower respiratory tract of companion birds. *Sem Avian Exotic Pet Med* 6:201-208, 1997.
25. Cooper JE, Harrison GJ: *Dermatology*. *In* Ritchie BW, Harrison GJ, Harrison LR (eds): *Avian Medicine: Principles and Application*. Brentwood, TN, HBD Int'l Inc, 1999, pp 997-1006.
26. Cray C, Zielezienski-Roberts K: Application of *Aspergillus* antigen assay in the diagnosis of aspergillosis. *Proc Assoc Avian Vet*, 1997, pp 219-221.
27. Curtis-Velasco M: Candidiasis and cryptococcosis in birds. *Sem Avian Exotic Pet Med* 9:75-81, 2000.
28. Dahlhausen RD, Lindstrom JG, Radabaugh CS: The use of terbinafine hydrochloride in the treatment of avian fungal disease. *Proc Assoc Avian Vet*, 2000, pp 35-39.
29. Dawson CO, Wheeldon EB, McNeil PE: Air sac and renal mucormycosis in an African grey parrot (*Psittacus erithacus*). *Avian Dis* 20:593-600, 1976.
30. Dennis PM, et al: Diagnosis and treatment of tracheal obstruction in a cockatiel (*Nymphicus hollandicus*). *J Avian Med Surg* 13:275-278, 1999.
31. Doneley B: Cutaneous cryptococcosis in an African grey parrot. *Proc Aust Comm Assoc Avian Vet*, 1994, p 247.
32. Dupont C, Carrier M, Higgins R: Bacterial and fungal flora in healthy eyes of birds of prey. *Can Vet J* 34:699-701, 1994.
33. Dustin LR: Surgery of the avian respiratory system. *Sem Avian Exotic Pet Med* 2:83-90, 1993.
34. Ellis DH, Pfeiffer TJ: Natural habitat of *Cryptococcus neoformans* var. *gatti*. *J Clin Microbiol* 228:1642-1644, 1990.
35. Fenwick B, Takeshita K, Wong A: A Moluccan cockatoo with disseminated cryptococcosis. *J Am Vet Med Assoc* 187:1210-1212, 1985.
36. Filippich IJ, Parker MG: Megabacteriosis and proventricular/ventricular disease in psittacines and passerines. *Proc Assoc Avian Vet*, 1994, pp 287-293.
37. Filippich IJ, Perry RA: Drug trials against megabacteria in budgerigars (*Melopsittacus undulatus*). *Aust Vet Pract* 23:184-189, 1993.
38. Flammer K: An overview of antifungal therapy in birds. *Proc Assoc Avian Vet*, 1993, pp 1-4.
39. Forbes NA: Aspergillosis in raptors. *Vet Rec* 128:263, 1991.
40. Forbes NA, Simpson GN, Goudswaard MF: Diagnosis of avian aspergillosis and treatment with itraconazole. *Vet Rec* 130:519-520, 1992.
41. Foster CS: Fungal keratitis. *In* Albert DM, Jakobiec FA, Robinson NL (eds): *Principles and Practice of Ophthalmology: Clinical Practice*. Philadelphia, WB Saunders Co, 1994, pp 171-179.
42. Franssen J, VanCulsem J: Fungal infections in birds in captivity (synopsis). *Assoc Avian Vet Today* 2:15, 1988.
43. Fudge AM, Reavill DR: Bird litter and aspergillosis warning. *J Avian Med Surg* 7:15, 1993.
44. Fudge AM: Avian clinical pathology, hematology and chemistry. *In* Altman RB, et al (eds): *Avian Medicine and Surgery*. Philadelphia, WB Saunders Co, 1997, pp 142-147.
45. Fudge AM, Reavill DR, Rosskopf WJ, Jr: Diagnosis and management of avian dyspnea: A review. *Proc Assoc Avian Vet*, 1993, pp 187-195.
46. Gerlach H: Megabacteriosis. *Sem Avian Exotic Pet Med* 10:12-19, 2001.
47. Graybill JR: New antifungal agents. *Euro J Clin Microbiol Infect Dis* 8:402-412, 1989.
48. Greenacre CS: Leg paresis in a black palm cockatoo caused by aspergillosis. *J Zoo Wildl Med* 23:122-126, 1992.
49. Greene R: The pulmonary aspergillosis: Three distinct entities or a spectrum of disease. *Radiology* 140:527-530, 1981.
50. Hanssen I: Pulmonary phycomycosis in captive rock ptarmigan (*Lagopus mutus*) and willow ptarmigan (*Lagopus lagopus*) chicks. *Acta Vet Scand* 16:134-136, 1975.
51. Harrison GJ: Selected surgical procedures. *In* Harrison GJ, Harrison LR (eds): *Clinical Avian Medicine and Surgery*. Philadelphia, WB Saunders Co, 1986, pp 581-582.
52. Henderson GM, Gulland FM, Hawkey CM: Haematological findings in budgerigars with megabacterium and *Trichomonas* infections associated with "going light." *Vet Rec* 123(19):492-494, 1988.
53. Hernandez-Divers, SJ: Endosurgical debridement and diode laser ablation of lung and air sac granulomas in psittacine birds. *J Avian Med Surg* 16:138-145, 2002.
54. Hill FI, Woodgater AJ, Lintott MA: Cryptococcosis in a North Island brown kiwi (*Apteryx australis mantelli*) in New Zealand. *J Med Vet Mycol* 33:305-309, 1995.
55. Hines RS, Sharkey P, Friday RB: Itraconazole treatment of pulmonary, ocular, and uropygial aspergillosis and candidiasis in

- birds-data from five clinical cases and controls. Proc Am Assoc Zoo Vet, 1990, pp 322-327.
56. Hoppes S, et al: Mycotic keratitis in a blue-fronted Amazon parrot (*Amazona aestiva*). J Avian Med Surg 14:185-189, 2000.
  57. Huchzermeyer FW, Henton MM, Keffen RH: High mortality associated with megabacteriosis of proventriculus and gizzard in ostrich chicks. Vet Rec 133:143-144, 1993.
  58. Ivey ES: Serologic and plasma protein electrophoretic findings in 7 psittacine birds with aspergillosis. J Avian Med Surg 14:103-106, 2000.
  59. Jenkins JR: Aspergillosis. Proc Assoc Avian Vet 1991, pp 328-330.
  60. Jones MP: Avian clinical pathology. Vet Clin No Am Exotic Anim Pract 1999;2:663-687.
  61. Jones MP, et al: Pharmacokinetic disposition of Itraconazole in red-tailed hawks (*Buteo jamaicensis*). J Avian Med Surg 14:15-22, 2000.
  62. Jordan FTW: Fungal diseases. In Jordan FTW (ed): Poultry Diseases 3<sup>rd</sup> ed. Philadelphia, Bailliere Tindall, 1990, pp 216-225.
  63. Joseph V, Pappagianis D, Reavill DR: Clotrimazole nebulization for the treatment of respiratory aspergillosis. Proc Assoc Avian Vet, 1994, pp 301-306.
  64. Kern TJ: Exotic animal ophthalmology. In Gelatt KN (ed): Veterinary Ophthalmology 3<sup>rd</sup> ed. Philadelphia, Lippincott, Williams & Wilkins, 1999, pp 1273-1305.
  65. Kerridge D: Mode of action of clinically important antifungal drugs. Adv Microbiol Physiol 27:1-72, 1998.
  66. Keymer IF: Mycosis. In Petrak ML (ed): Diseases of Cage and Aviary Birds 2<sup>nd</sup> ed. Philadelphia, Lea & Febiger, 1982, pp 599-605.
  67. Kon VM, Linton AH: Mucormycotic infection of birds. Vet Rec 73:1008, 1961.
  68. Kwon-Chung KJ: Cryptococcosis. In Kwon-Chung KJ, Bennett JE (eds): Medical Mycology. Philadelphia, Lea & Febiger, 1992, pp 397-446.
  69. Lehrer RI, et al: Mucormycosis. Ann Intern Med 93:93-108, 1980.
  70. Lumeij JT, Gorgevska D, Woestenborghs R: Plasma and tissue concentrations of itraconazole in racing pigeons (*Columba livia domestica*). J Avian Med Surg 9:32-35, 1995.
  71. Luttrull JK, et al: Treatment of ocular fungal infections with oral fluconazole. Amer J Ophthalmol 119:477-481, 1994.
  72. Lyman CA, Walsh TJ: Systematically administered antifungal agents. A review of their clinical pharmacology and therapeutic applications. Drugs 44:9-35, 1992.
  73. McMillian M, Petrak M: Retrospective study of aspergillosis in pet birds. J Avian Med Surg 3:211-215, 1989.
  74. Micalizzi C, Persi A, Parodi A: Primary cutaneous cryptococcosis in an immunocompetent pigeon keeper. Clin Exp Dermatol 22:195-197, 1997.
  75. Mitchell G, Esnouf D, Pritchard R: Mucormycosis in canaries (*Serinus canaries*) fed damp germinated seed. Vet Pathol 23:625-627, 1986.
  76. Moore RP, Snowden KF, Phalen DN: A method of preventing transmission of so-called "megabacteria" in budgerigars (*Melopsittacus undulatus*). J Avian Med Surg 4:283-287, 2001.
  77. Mori T, et al: Systemic aspergillosis caused by an aflatoxin-producing strain of *Aspergillus flavus*. Med Mycol 36:107-112, 1998.
  78. Nosanchuck JD, et al: Evidence of zoonotic transmission of *Cryptococcus neoformans* from a pet cockatoo to an immunocompromised patient. Ann Intern Med 132:205-208, 2000.
  79. Oglesbee BL: Mycotic diseases. In Altman RB, et al (eds): Avian Medicine and Surgery. Philadelphia, WB Saunders Co, 1997, pp 323-331.
  80. Orcutt CJ, Bartick TE: Mucormycotic meningoencephalitis and pneumonia in a chattering lory (*Lorius Garrulus*). J Avian Med Surg 8:85-89, 1994.
  81. Orosz SE, Frazier DL: Antifungal agents: A review of their pharmacology and therapeutic indications. J Avian Med Surg 9:8-18, 1995.
  82. Orosz SE, et al: Pharmacokinetic properties of itraconazole in blue-fronted Amazon parrots (*Amazona aestiva aestiva*). J Avian Med Surg 10:168-173, 1996.
  83. Orosz SE, et al: The effects of formulation on the systemic availability of itraconazole in pigeons. J Avian Med Surg 9:255-262, 1995.
  84. Panigrahy B, et al: Candidiasis in cockatiel nestlings and mucormycosis in a pigeon. Avian Dis 23:757-760, 1979.
  85. Pass DL: The pathology of the avian integument: A review. Avian Pathol 18:17, 1989.
  86. Paul-Murphy J: Avian neurology. Proc Assoc Avian Vet, 1992, pp 420-432.
  87. Phalen DN: Respiratory medicine of cage and aviary birds. Vet Clin No Am Exotic Anim Pract 3:423-452, 2000.
  88. Phalen DN, Tomaszewski E, Davis A: Investigation into the detection, treatment, and pathogenicity of avian gastric yeast. Proc Assoc Avian Vet, 2002, pp 49-51.
  89. Pye G: Surgery of the avian respiratory system. Vet Clin No Am Exotic Pet Med 3:693-713, 2000.
  90. Raidal SR, Butler R: Chronic rhinosinusitis and rhamphotheca destruction in a Major Mitchell's cockatoo (*Cacatua leadbeateri*) due to *Cryptococcus neoformans* var. *gattii*. J Avian Med Surg 15:121-122, 2001.
  91. Ravelhofer-Rotheneder K, et al: Untersuchungen zur taxonomischen Einordnung von "Megabakterien." Proc XII DVG-Tagung über Vogelkrankheiten, 2000, p 15.
  92. Redig PT: Mycotic infections of birds of prey. In Fowler ME (ed): Zoo and Wild Animal Medicine: Current Therapy 3. Philadelphia, WB Saunders Co, 1993, pp 178-181.
  93. Redig PT, Orosz S, Cray C: The ELISA as a management guide for aspergillosis in raptors. Proc Assoc Avian Vet, 1997, pp 99-104.
  94. Redig P: Diagnosis of avian aspergillosis. Proc Assoc Avian Vet, 1999, pp 355-357.
  95. Redig PT: Aspergillosis. In Samour J (ed): Avian Medicine. Philadelphia, Mosby, 2000, pp 275-287.
  96. Reidarson TH, McBain J: Serum protein electrophoresis and *Aspergillus* antibody titers as an aid to diagnosis of aspergillosis in penguins. Proc Assoc Avian Vet, 1995, pp 61-64.
  97. Richard JL, et al: Recent studies on aspergillosis in turkey poults. Mycopathologia 87:3-11, 1984.
  98. Rode J, Bartlow S, Ludders J: Ventilation through an air sac cannula during tracheal obstruction in ducks. J Avian Med Surg 4:98-102, 1990.
  99. Rossi G: Histological and immunohistochemical findings in proventricular mucosa of chickens experimentally infected with "megabacterium." Proc Euro Soc Vet Pathol, 2000, p 156.
  100. Roskopf WJ, Woerpel RW: Cryptococcosis in a thick-billed parrot. Proc Assoc Avian Vet, 1984, pp 281-288.
  101. Roskopf WJ: Surgery of the avian respiratory system. Proc Amer Coll Vet Surg, 1988, pp 373-382.
  102. Rupiper DJ: Diseases that affect race performance of homing pigeons. Part II: bacterial, fungal, and parasitic diseases. J Avian Med Surg 12:138-148, 1998.
  103. Samour JH, Naldo, JL: Diagnosis and therapeutic management of candidiasis in falcons in Saudi Arabia. J Avian Med Surg 16:129-132, 2002.
  104. Scanlan CM, Graham DL: Characterization of a gram-positive bacterium from the proventriculus of budgerigars (*Melopsittacus undulatus*). Avian Dis 34:779-786, 1990.
  105. Shivaprasad HL: Poultry ophthalmology. In Gelatt K (ed): Veterinary Ophthalmology 3<sup>rd</sup> ed. Philadelphia, Lippincott, Williams & Wilkins, 1999, pp 1177-1207.
  106. Speed B, Dunt D: Clinical and host differences between infections with the two varieties of *Cryptococcus neoformans*. Clin Infect Dis 21:28-34, 1995.
  107. Stanford M: Use of F10 in Psittacines. Exotic DVM 3(4)18, 2001.
  108. Suedmeyer WK, Bermudez A, Fales W: Treatment of epidermal cysts associated with *Aspergillus fumigatus* and an *Alternaria* sp. in a silky bantam chicken (*Gallus gallus*) Proc Am Assoc Zoo Vet Int Assoc Aquat Anim Med, 2000, p 307.
  109. Taylor M: Endoscopic diagnosis of avian respiratory tract diseases. Sem Avian Exotic Pet Med 6:187-194, 2000.
  110. Tomaszewski EK, et al: Phylogenetic analysis indicates the "megabacterium" of birds is a novel anamorphic ascomycetous yeast, *Macrorhabdus ornithogaster*, gen. nov., sp. nov. Int J Sys Evol Micro, 2002.
  111. Tudor DC: Mycotic infections of feathers as a cause of feather pulling in pigeons and psittacine birds. Vet Med Small Anim Clin 78:249-253, 1983.
  112. Tully TN: Avian respiratory diseases: Clinical overview. J Avian Med Surg 9:162-174, 1995.
  113. Ungerechts N: Radiographic signs of proventricular infection with "megabacteria." J Avian Med Surg 4:203, 1990.
  114. Van Cutsem J, Van Gerven F, Janssen PAJ: Activity of orally, topically, and parenterally administered itraconazole in the treatment of superficial and deep mycoses: Animal models. Rev Infect Dis 9:15-32, 1987.
  115. Van Cutsem J, Janssen PAJ: In vitro and in vivo models to study the activity of antifungals against *Aspergillus*. In Vanden Bossche H, MacKenzie DWK, Cauwenbergh G (eds): *Aspergillus* and Aspergillosis. New York, Plenum Press, 1987, pp 215-227.
  116. Van Der Hayden N: Aspergillosis in psittacine chicks. Proc Assoc Avian Vet, 1993, pp 1-6.
  117. VanHerck H, et al: A bacterial proventriculitis in canaries (*Serinus canaria*). Avian Pathol 13:561-572, 1984.
  118. Van Sant F: Impression cytology: New insights into avian skin flora. Proc Assoc Avian Vet, 1999, pp 139-141.
  119. Vaughn S: What is your diagnosis? J Avian Med Surg 10:33-35, 1996.
  120. Wallach JD, Boever WJ: Diseases of Exotic Animals. Philadelphia, WB Saunders Co, 1983, pp 856-946.
  121. Ward FP, Fairchild DG, Vuicich JV: Pulmonary aspergillosis in prairie falcon nest mates. J Wildl Dis 6:80-83, 1970.
  122. Wolf ED, Amass K, Olsen J: Survey of conjunctival flora in the eye of clinically captive exotic birds. J Am Vet Med Assoc 11:1232-1233, 1983.
  123. Wolff, PL, Petrini KR, Kolmstetter C: An outbreak of aspergillosis in crested wood partridges (*Rollulus roulroul*). J Zoo Wildl Med 23:108-112, 1992.