

Avian parasites range from single-celled protozoans that develop either intracellularly or extracellularly to multicellular helminths and arthropods. The effects of an infection can vary from benign to acute deaths. Parasitic life cycles may be direct or complex indirect cycles requiring various arthropod or animal hosts. Some species of parasites can infect nearly every organ system, although individual genera will inhabit specific organs or tissues. For example, mature tapeworms (Cestoda) and spiny-headed worms (Acanthocephala) are restricted to the small intestines. Mature flukes (Trematoda) occur in the intestines, liver, kidney, air sacs, oviducts, blood vessels and on the surface of the eyes. Adult roundworms (Nematoda) parasitize the crop, proventriculus, ventriculus, intestines, ceca, body cavities, brain, surface and periorbital tissues of the eyes, heart and subcutaneous tissues. Mites (Acarina) live in and on the skin, feather shafts and follicles, choanal slit, nasal passages, trachea and air sacs. Immature and mature biting lice and ticks remain on the integument. Single-celled organisms with discrete nuclei (Protozoa) may be found in the lumen of the intestinal tract, extracellularly in the blood or within cells of many tissues.

It should be stressed that identifying a parasite (or parasite egg) does not imply clinical disease. Many parasites coexist with their avian hosts without causing pathologic changes. Long-term symbiotic parasite-host relationships are usually characterized by benign infections compared with parasites that have been recently introduced to a new host. The fact that companion and aviary birds from widely varying geographic regions are combined creates an opportunity for exposure of a naive host to parasitic organisms that may cause few problems in their natural host. Parasites that are apathogenic in endemic avifauna can cause chronic disease or rapid death in unnatural hosts.

CHAPTER

36

PARASITES

Ellis C. Greiner
Branson W. Ritchie

With companion and aviary bird species, parasitic infections are most common in birds that are recently imported or that have access to the ground. Some parasites are host-specific, while others can infect a wide range of avian species. Free-ranging birds should be restricted from an aviary to prevent them from serving as sources for parasites. Parasitic problems are best managed by designing facilities that restrict a bird's access to infectious stages of a parasite and by practicing sound hygiene. Birds maintained indoors or in suspended welded wire enclosures are unlikely to have parasites that have an indirect transmission cycle. In contrast, parasitic infections are common in countries where birds are maintained in walk-in type aviaries with access to the ground.

Treatment for parasitic infections should include appropriate anthelmintics (when available) and management changes that will prevent reinfection (Table 36.1). Relatively apathogenic parasites may cause severe clinical disease in birds that are immunosuppressed or stressed or have concomitant infections.

TABLE 36.1 Suggested Parasite Treatments

Parasites	Therapy
<i>Haemoproteus</i>	Not recommended in asymptomatic birds
<i>Leucocytozoon</i>	Pyrimethamine, Clopidol (0.0215 to 0.025%) in food as preventative
<i>Plasmodium</i>	Chloroquine phosphate, Primaquine
<i>Giardia</i>	Metronidazole
<i>Histomonas</i>	Ipronidazole, Dimetrodazole
<i>Atoxoplasma</i>	See text
<i>Cryptosporidium</i>	No effective therapy
<i>Sarcocystis</i>	Pyrimethamine, Trimethoprim, Sulfadiazine
Cestodes	Praziquantel
Ascarids	Pyrantel pamoate, Piperazine
<i>Oxyspirura</i>	Ivermectin
<i>Capillaria</i>	Mebendazole, Fenbendazole, Ivermectin (resistant strains occur)
<i>Syngamus</i>	Ivermectin, Physical removal
<i>Knemidokoptes</i>	Topical ivermectin
<i>Sternostoma</i>	Ivermectin, Physical removal
Gapeworms	Thiabendazole, Mebendazole
Trichomonads	Dimetronidazole, Metronidazole
Coccidia	Metronidazole

Life cycles for most avian parasites are poorly understood. Much of the currently available information is based on comparative data from similar taxa in other

hosts. Diagnostic stages of most avian parasites have not been matched to the adults of the same species and thus characterization is usually limited to order or superfamily. Avian parasitology will be enhanced by cooperation among aviculturists, avian veterinarians and parasitologists.

Diagnosis of Parasites

Parasitic infections in birds may be diagnosed through examining samples from living birds or through necropsy of affected individuals or representatives of flocks.

It is important to determine which parasites are present because: 1) related parasite/host systems may cause clinical signs similar to the ones being observed, providing the clinician with information on potential life cycles; 2) determining which groups of parasite(s) are present will ensure the selection of appropriate antiparasitic agents; and 3) determining a potential source of infection would help in designing a preventive program for individual birds and the flock.

TABLE 36.2 Common Parasites in Companion Birds

African Grey Parrots	Tapeworms (common), blood parasites* (occasional)
Australian Parakeets	Proventricular worms (common), nematodes (frequent)
Budgerigars	<i>Trichomonas</i> (common), <i>Giardia</i> (common)
Canaries	Air sac mites
Cockatiels	Ascarids* (common), <i>Giardia</i> (frequent)
Cockatoos	Tapeworms (common), <i>Haemoproteus</i> *, microfilaria, liver flukes*
Finches	Air sac mites, tapeworms (common), <i>Trichomonas</i> *
Lorikeets	Coccidia, roundworms* (frequent)
Macaws	<i>Capillaria</i> (frequent, imports), ascarids* (common)
Toucans	<i>Giardia</i> (common), coccidia (frequent)

* Relatively uncommon in captive-bred birds in the United States

Diagnosis in the Living Bird

Depending on the parasite, appropriate antemortem diagnostic samples could include feces, blood, tissue

GREINER'S TENETS FOR FECAL EXAMINATION⁴⁴

1. Examine an adequate quantity (1 to 2 grams) of fresh feces. Some nematode eggs will larvate if allowed to age, producing atypical eggs or larvae that are difficult to identify. Some parasitic forms (trophozoites of *Giardia* for example) are fragile and will perish if the sample is not examined immediately.
2. Collect feces per cloaca or from nonabsorbent cage lining such as waxed paper or aluminum foil. Using nonabsorbent material to collect feces provides a moist sample of greater volume when compared to scraping a sample off newsprint or paper toweling. Samples collected from corn cob, wood shavings or cat litter should not be considered diagnostic.
3. Conduct the test that specifically demonstrates the parasite that is most likely to be causing the clinical changes. Fluke eggs cannot be demonstrated by flotation. Trophozoites of *Giardia* and *Trichomonas* will be destroyed if placed into saturated salt or sugar flotation solutions. *Giardia* trophozoites die in tap water and are best identified by using warm saline or lactated Ringer's solution as a diluent.
4. Examine each prepared sample completely and systematically. The low power objective (10x) should be used for scanning. The high dry objective can be used to magnify and examine a particular structure. Scan the coverslip beginning at one corner and traversing the length of the coverslip, then move the slide to the next field of view and reverse the field of movement. Repeating this procedure until the entire coverslip has been viewed will provide a systematic examination of the total preparation and reduce the likelihood of missing a parasite. Examine the entire slide and do not stop when eggs of one kind have been identified. Some helminths produce very few eggs that may not be detected unless the entire slide is examined.
5. Standardize procedures so that results are repeatable and comparable. If a diagnostic technique is not standardized, the results are of limited value. Egg counts are of little value because there is no direct correlation between the number of eggs per gram of feces and the number of adult parasites present. Comparing egg counts between treated and untreated birds may provide some information on the effect of an anthelmintic.

biopsies or integument for the detection of intact parasites, eggs or intermediate life forms. Specific diagnostic procedures are dictated by the size and species of bird, clinical signs and the types of parasites that might be contributing to the problems.

Egg characteristics that should be evaluated include shape, size (determined by using a calibrated ocular micrometer), color (colorless, yellowish to brown), texture (smooth, pitted, mammillated), single operculum, bipolar plugs, stage of development (single cell, morula or larvae) and type of larva present in the egg (nematode larva, hexacanth larva, miracidium or acanthor).

The diagnostic stage of most avian helminths is an egg that is detected in the feces by either flotation or sedimentation. The flotation method will remove ex-

traneous debris and concentrate the eggs of nematodes, cestodes and acanthocephala and the cysts and oocysts of protozoa. The most generally used flotation medium is saturated sodium nitrate (568 g sodium nitrate/ 1000 ml water). Sheather's sugar solution (500 g table sugar, 320 ml water and 6.5 g phenol crystals) is most commonly used to detect coccidian oocysts. Saturated zinc sulfate (336 g zinc sulfate/ 1000 ml water) is best for concentrating cysts of *Giardia* and may be better for detecting spiruroid eggs than sodium nitrate.

Flotation can be performed by mixing feces in a volume of flotation medium and passing the mixture through a piece of double-layer gauze or cheesecloth placed on top of a vertical tube. The tube should be filled until a slight positive meniscus is formed. A coverslip is placed on top of the tube and allowed to stand for ten minutes. As an alternative technique, the feces can be placed on a gauze pad on top of a 15 ml centrifuge tube and washed with lactated Ringer's solution. The collected fluid is then centrifuged at 1200 to 1500 rpm for ten minutes and the sediment is mixed in the appropriate flotation medium. The coverslip from either method is then examined microscopically.

TABLE 36.3 Best Tests for Detecting Avian Parasites

Parasite	Test
<i>Hexamita</i> , <i>Giardia</i> , <i>Trichomonas</i>	Fresh direct mount with warm LRS (not H ₂ O)
Coccidia oocyst	Flotation - Sheather's sugar
<i>Giardia</i> , spiruroid eggs	Flotation - Zinc sulfate
Nematodes, cestodes, acanthocephala	Flotation - Sodium nitrate
Flukes	Sedimentation
<i>Plasmodium</i> , <i>Haemoproteus</i> , <i>Leucocytozoon</i> , <i>Atoxoplasma</i> , <i>Trypanosoma</i> , microfilaria	Blood smear - Wright's stain (see Color 9)
Microfilaria, <i>Trypanosoma</i>	PCV tube, inspect at blood plasma interface using microscope

Fecal sedimentation is used primarily for the detection of fluke eggs that do not float in commonly used media. Feces is mixed in a liquid soap-in-water solution (0.1 to 1%) and allowed to stand for five minutes without centrifugation. The supernatant is gently removed and the tube is refilled with soapy water and allowed to stand for another five minutes. This procedure removes particulate material and concentrates the fluke eggs. It can also be used in place of flotation to detect eggs and cysts but is more time-consuming and may not be as sensitive as a flotation method.

A direct smear is best for detecting motile protozoan trophozoites (*Giardia*, *Trichomonas* or *Hexamita*). Samples are not diagnostic if they are more than 15 minutes old. Feces or tissue swabs are mixed with LRS or normal saline (0.85% sodium chloride), not tap water. The proper density of the preparation is achieved when newsprint can be easily read through the preparation. The microscope light should be adjusted to provide maximum contrast. The morphology of the parasites may be confirmed by fixing feces in polyvinyl alcohol and staining a slide preparation with trichrome.

Blood films are used to detect avian hematozoa, including microfilariae of filarial worms. Commonly identified blood parasites include intracellular stages of *Plasmodium*, *Haemoproteus*, *Leucocytozoon* and "*Atoxoplasma*," and extracellular stages of *Trypanosoma* and microfilariae from various filarial worms. Blood smears may be made on microscope slides or on coverslips. Coverslips have the advantage of being in view when mounted on slides and the sample is protected from being wiped off the slide. Giemsa or Wright's/Giemsa staining procedures provide the best results and long lasting stain quality (see Chapter 9). Alternatively, blood may be collected in a hematocrit tube and centrifuged, and the plasma/cell interface examined.

Arthropods collected for identification should be fixed and stored in 70% ethanol. Larvae of myiasis-causing flies should be killed by placing them briefly in boiling water and then transferring them to 70% ethanol. Mites, ticks, fleas and lice can be placed directly into 70% alcohol. Arthropods may be removed from the skin or feathers with forceps, or those living under crusting skin can be collected by scraping the encrusted area with a dull scalpel and allowing the crusts to fall into a petri dish containing 70% ethanol. A dissecting microscope can be used to demonstrate the mites. Arthropods present in the choanal slit can be collected with a moistened cotton-tipped swab.

Feather mites can be collected by placing the affected feather in 70% ethanol. Quill mites (ones living in the shaft of the feather) may be detected by microscopically examining the transparent portion of plucked primary feathers or coverts. These parasites can be recovered by slitting the shaft lengthwise and placing it in alcohol. Lice can be located by running a finger through the feathers. Bird fleas can be manually removed. However the mouth parts of some fleas, such as *Echidnophaga*, may remain attached



FIG 36.1 Many of the biting and chewing flies that live in and on the feathers of birds (such as this hippoboscidae) are flattened and move quickly, making it difficult to collect them for identification.

to the bird (see Color 8). Hippoboscid flies are flattened, move rapidly under the feathers and are difficult to catch (Figure 36.1). The use of a pyrethrin-based flea spray, designed for puppies and kittens, is a safe and easy way to collect topical parasites from birds. A minimal dose (one drop under each wing of a cockatiel) is effective.

Diagnostic Stages Found in Birds

The following information is a review of the few references on the partial or generic identification of parasitic life stages passed by birds. Figures 36.2 to 36.4 illustrate fluke eggs that were detected from sedimentation. Helminth eggs that were recovered by flotation are shown in Figures 36.5 to 36.8. Figures 36.9 to 36.21 are nematodes eggs. Figure 36.22 is the egg of an acanthocephalan and Figure 36.23 is a mite egg. Most mite eggs are large (100 μm) and often contain a larva with jointed legs. Note all mite eggs seen in fecals do not indicate acariasis as some are normal grain mites being consumed in the bird's food. Figures 36.24 to 36.27 are coccidian oocysts that have been sporulated. They would appear with a granular spherical mass in the center of the oocyst when passed in the feces, and must be sporulated to determine the genus.

Diagnosis in Dead Birds

Any bird that dies should be necropsied and tissues should be collected for histopathology. If parasites are identified, they should be collected for classification. Gross and histologic lesions should be correlated with any recovered parasite to determine if the

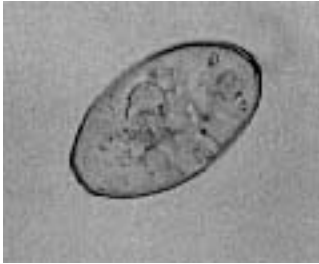

FIG 36.2 *Orchipedium* egg from Sandhill Crane, 77 x 45 μm , with prominent operculum.

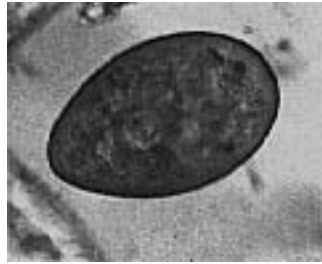

FIG 36.3 Strigeid egg from Bald Eagle, 95 x 60 μm , with obvious operculum.

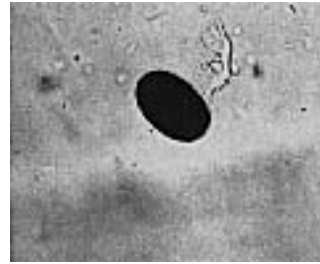


FIG 36.4 Dicrocoelid egg from macaw, 33 x 22 μm , with inapparent operculum and typical dark brown coloration.

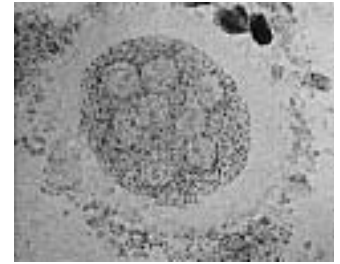


FIG 36.5 *Raillietina* tapeworm egg packet from an African Grey Parrot, clear halo, 223 x 193 μm , several eggs each with oncosphere bound in a gelatinous mass.

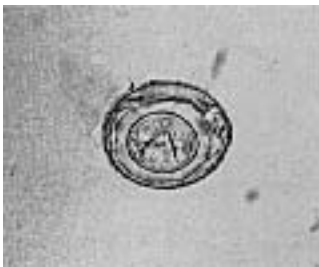

FIG 36.6 Tapeworm egg from peafowl, 50 x 38 μm , note 2 of 3 pairs of oncosphere hooks in focus.

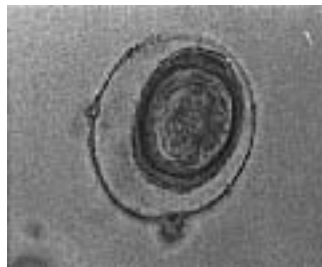

FIG 36.7 Tapeworm egg from cockatiel, 74 x 68 μm , outer membrane intact and most hooks on oncosphere in focus.

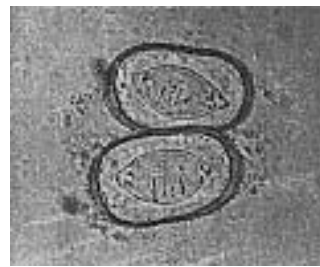


FIG 36.8 Tapeworm egg (possibly *Pulluterina* sp.) from unidentified parrot, 62 x 26 μm , four of six hooks on oncosphere in focus and rectangular shell with distinctive shape of oncosphere.

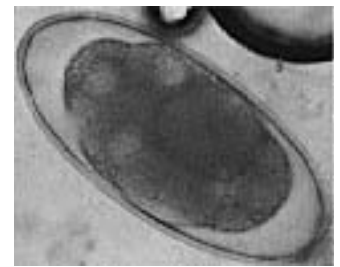

FIG 36.9 *Deletrocephalus* egg from rhea, 169 x 77 μm , very large.

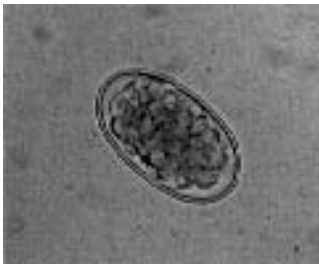

FIG 36.10 *Codiostomum* egg from ostrich, 60 x 35 μm .

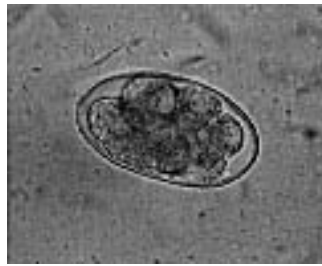

FIG 36.11 *Trichostrongylus* egg from wild turkey, 67 x 37 μm .

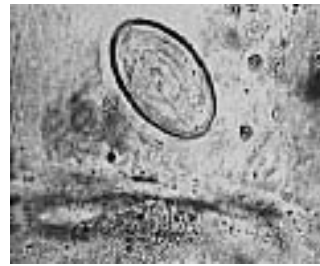

FIG 36.12 *Syngamus* egg from Barred Owl, 54 x 33 μm , note shape and polar plugs.

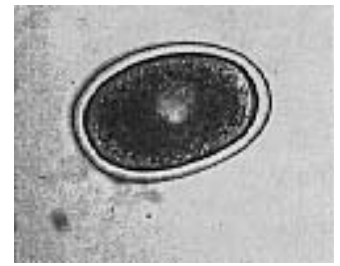


FIG 36.13 *Ascaridia* egg from macaw, 77 x 52 μm , smooth, thick, ellipsoid shell.

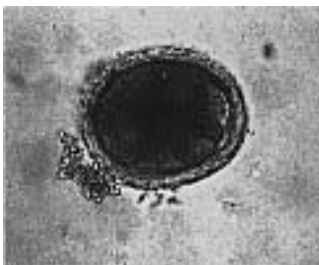

FIG 36.14 *Porrocaecum* egg from Bald Eagle, 66 x 55 μm , rough-walled, subspherical shape.

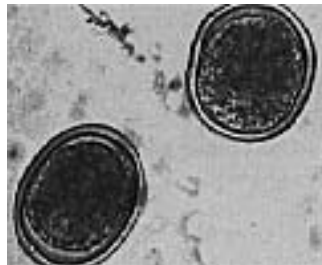

FIG 36.15 *Contraecaecum* egg from pelican, 65 x 50 μm , smooth egg wall and subspherical.

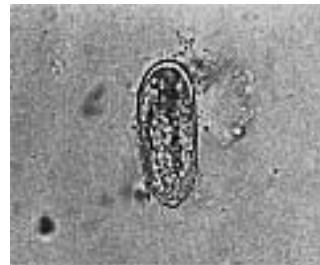

FIG 36.16 *Habronema*-like egg from macaw, 57 x 22 μm , elongate, larvated.

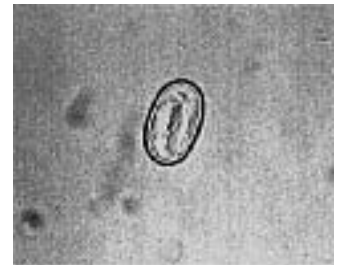

FIG 36.17 Spiruroid egg from cockatiel, 35 x 22 μm , thick-walled, symmetrical and larvated.

Figures 36.2 through 36.27 courtesy of Ellis Greiner.

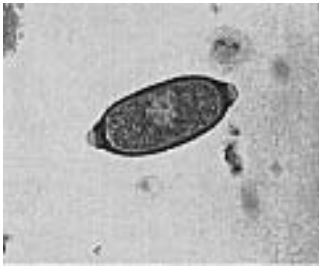

FIG 36.18 *Capillaria* egg from Bald Eagle, 62 x 29 μ m, bipolar plugs and pitted wall.

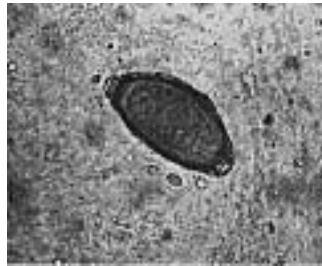

FIG 36.19 *Capillaria* egg from Barred Owl, 59 x 29 μ m.

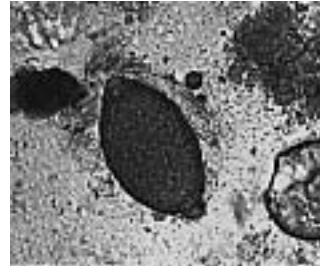


FIG 36.20 *Capillaria* egg from Great Horned Owl, 64 x 36 μ m.

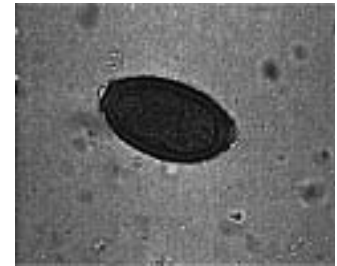


FIG 36.21 *Capillaria* egg from pigeon, 52 x 31 μ m.




FIG 36.22 *Centrorchynchus* egg (an acanthocephalan), 58 x 23 μ m, laminated-appearing egg with central larva (acanthor).

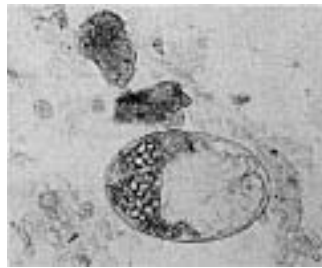


FIG 36.23 Mite egg from peafowl, 157 x 134 μ m.

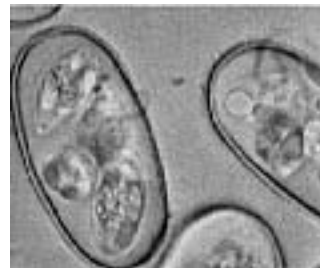

FIG 36.24 *Eimeria* oocyst from Blue-fronted Amazon, 47 x 25 μ m, note the 4 sporocysts each with two sporozoites.

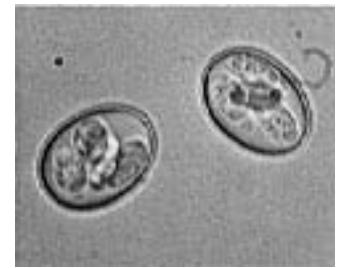


FIG 36.25 *Eimeria forresteri* oocyst from Toco Toucan, 23 x 18 μ m, same sporocysts arrangement as Figure 36.24.

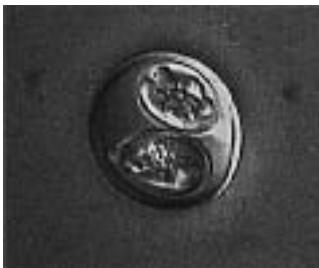

FIG 36.26 *Isospora* oocyst from House Sparrow, 25 x 25 μ m, note 2 sporocysts each with four sporozoites.

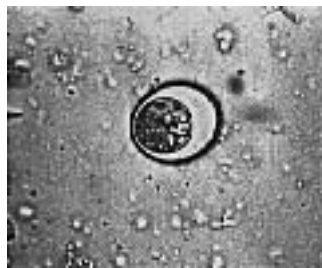

FIG 36.27 *Caryospora* oocyst from Red-shouldered Hawk, 36 x 31 μ m, note single sporocyst and eight sporozoites.

organism is contributing to a specific set of clinical changes (Figure 36.28).

It is always a good policy to contact the parasitologist and request special submission instructions. Parasites for classification should be collected from each affected organ, placed in separate containers and fixed as discussed below. The host species, host identification number, location of parasite in the host and date collected should be written in soft pencil on a good quality white paper and included in the vial with the specimens. Other useful information includes whether the bird was imported or captive-raised, its duration in captivity and the number of birds affected.

The complete gastrointestinal tract should be opened lengthwise, section by section. In small birds, each section of bowel may be opened in a series of petri dishes containing water. In large birds, the bowel contents should be washed through #40 and #100 standard sieves. The mucosa should be scraped to free attached helminths, and the residue on the sieve should be back-flushed into a dish and evaluated for the presence of parasites. Detection and recovery of helminths can also be accomplished by placing the gut contents into one-liter flasks and allowing a sediment to form. This procedure is repeated until the water remains clear. Parenchymous organs should be sequentially sliced and evaluated for the presence of helminths. The body cavities, air sacs and orbits of the eyes should be examined grossly for worms. Skin over swellings on the feet or legs should be excised, and the area should be examined for the presence of adult filarial worms. All recoverable parasites should be collected to maximize the information that can be ascertained from the infection.

Nematodes should be placed briefly in full-strength glacial acetic acid or hot 70% ethanol. This process should kill and fix the nematodes in a straight, uncoiled manner. They should then be transferred into glycerin alcohol (9.0 parts 70% ethanol and 1.0 part glycerin) for storage.

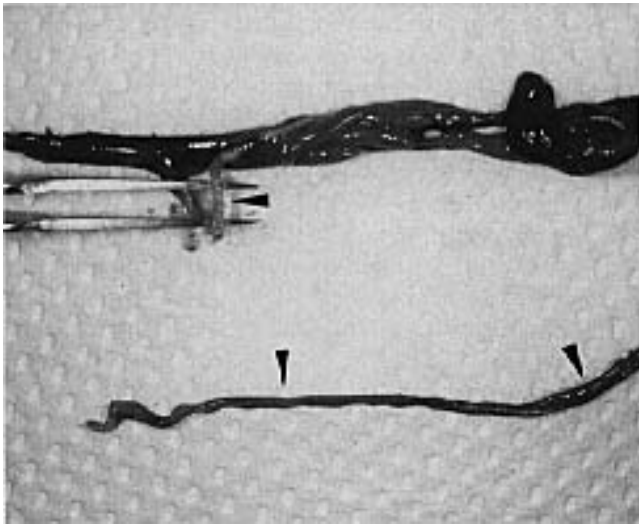


FIG 36.28 An adult African Grey Parrot was presented with a two-week history of progressive diarrhea. The bird was emaciated and dehydrated and had dried excrement around the vent. The bird did not respond to supportive care and died several hours after presentation. Tapeworms (arrows) were identified in the intestinal tract. Note the dark (hemorrhagic) bowel loops.

Cestodes should be relaxed in tap water in a refrigerator for two to four hours and then fixed in AFA (8.5 parts 70% ethanol, 1.0 part full strength formalin and 0.5 part glacial acetic acid). The parasites collected should have an intact scolex (holdfast), which is important in tapeworm identification.

Trematodes should be relaxed by placing them in tap water in the refrigerator for 30 to 60 minutes. Thin-bodied flukes should be placed into AFA. Thick-bodied flukes should be gently held in place between two glass microscope slides while AFA is instilled between the slides. After a few minutes, the top slide is removed.

Acanthocephalans should be gently removed from the gut wall to prevent rupture of the parasite, which will destroy the hydraulic system that extends the proboscis (making identification of the parasite nearly impossible). Acanthocephalans may lose their torpor and detach from the gut wall when the host dies. They may then resemble a yellowish to whitish, short, wrinkled tapeworm. Placing the parasite into tap water overnight in a refrigerator may cause the proboscis to extend, at which point the parasite is fixed in AFA.

A fecal examination should be performed at necropsy so that eggs detected by fecal flotation or sedimentation can be compared to the eggs in the adult worms.

Clinically Significant Parasites

Protozoa

The single-celled parasites include the malarial parasites (*Plasmodium* spp.) and their relatives (*Haemoproteus* spp. and *Leucocytozoon* spp.), the coccidians (*Eimeria*, *Isospora*, *Sarcocystis* and *Toxoplasma*), the microsporidians (*Encephalitozoon*) and flagellates in the gastrointestinal tract (*Giardia*, *Trichomonas* and *Hexamita*) and the peripheral circulation (*Trypanosoma*) (Table 36.5).

Gastrointestinal Flagellates

Protozoans with flagella that reside in the gastrointestinal tract of psittacine birds include *Trichomonas gallinae*, *Hexamita* and *Giardia* spp.

- ***Trichomonas*:** Trichomonads do not require an intermediate host or vector and are transmitted through direct contact or through ingestion of contaminated water or food. Infected adults can transmit the parasite to their chicks during feeding activities. Parental feeding of young is an effective method of parasite transmission. There is no resistant cyst form, and only the motile trophozoite has been described. This extracellular parasite measures 8 to 14 μm in length (may vary in different host species), has four free anterior flagella and possesses an undulating membrane that creates a wave-like appearance along the cell surface. It moves in a jerky manner and the body diameter remains constant as it moves.

Depending on the species, infections may be localized in the mouth, oropharynx, esophagus, crop and trachea, or the pulmonary and hepatic tissues can be invaded. Pathogenic strains cause inflammation and white plaques on the gastrointestinal mucosa or necrosis with an accumulation of cheesy material that might occlude the esophagus and trachea. Overcrowding and poor hygiene may potentiate infections in individual birds as well as increasing the incidence of disease in a flock. Infections in young birds are generally associated with poor growth and high mortality. In adult birds, infections are usually characterized by emaciation, dyspnea or vomiting. A pathogenic strain caused the death of all ages of naive pigeons four to 18 days after infection. Blue-fronted Amazon Parrots, cockatiels and budgerigars are

known to be susceptible.^{40,54,79,104} Trichomoniasis is particularly common in pigeons and raptors (frounce) (see Chapter 8). Pathogenic and nonpathogenic strains of *T. gallinae* have been described in pigeons; thus, not all infections may be a threat to the host. Feeding pigeons to captive raptors (especially species that do not normally eat pigeons such as eagles and large hawks) may result in the transmission of *Trichomonas*. Advanced cases with large necrotic masses are difficult to treat and generally have a poor prognosis (see Chapter 19).

- **Giardia:** The *Giardia* sp. recovered from budgerigars appears to be morphologically distinct from those found in other animals and has been identified as *G. psittaci*.³¹ Most reports of giardiasis in psittacine birds involve budgerigars, cockatiels, lovebirds and Grey-cheeked Parakeets. Rarely, infections may be detected in Amazon parrots, conures, cockatoos, macaws, toucans, Galliformes and Anseriformes.^{15,38,97} *Giardia* has not been reported in finches or canaries.

Giardia sp. is commonly found in the feces of asymptomatic adult budgerigars and cockatiels, suggesting an asymptomatic carrier state (see Color 8). In a group of 77 parakeets from several sources, 66% of the birds were found to be shedding *Giardia*.⁸⁴ In another study, 70% of cockatiels, 55% of budgerigars, 25% of lovebirds, 5% of Grey-cheeked Parakeets and less than 5% of other psittacine birds were found to be shedding giardia. Asymptomatic birds may intermittently shed the parasite.⁸⁴

Psittacine birds with giardiasis may be asymptomatic, or the birds may exhibit signs of loose, malodorous stools, mucoid diarrhea, debilitation, gram-negative enteritis, anorexia, depression, recurrent yeast infections, eosinophilia and hypoproteinemia. Dry skin and feather picking, particularly in the carpal-metacarpal, flank, axilla and lower leg areas, has been described as a clinical sign of giardiasis in budgerigars and cockatiels (see Chapter 24). Giardiasis can cause poor growth and high mortality in budgerigar and cockatiel neonates. Mortality rates of 20 to 50% have been described in some infected budgerigar flocks.⁸⁴

In mammals, *Giardia* is frequently considered an opportunistic pathogen that requires an immunocompromised host. The role that the immune system plays in preventing a bird from developing giardiasis has not been determined. However, many clinically affected psittacine birds are fed marginal diets, are maintained in overcrowded, hygienically unsound

conditions or are heavily inbred. Birds that recover from an infection are susceptible to re-infection indicating that a long-lasting protective immune response does not occur with infection.

Giardia spp. have a motile trophozoite and a cyst stage that can be identified in the feces or from mucosal scrapings collected at necropsy (Figure 36.29). Direct transmission occurs following the ingestion of food contaminated with feces from infected birds. The environmentally stable cysts can serve as a source of infection to other hosts. *Giardia* trophozoites are not stable outside of the host.

Cytologic preparations must be examined within ten minutes of collection or trophozoites may not be recognized. False-negative results are common if the feces is over ten minutes old when it is examined. Trophozoites are flat and move in a smooth rolling manner. If a fecal sample cannot be examined immediately, it should be fixed in polyvinyl alcohol for trichrome staining.

Multiple, fresh, direct fecal smears stained with carbol fuchsin (one minute) or iodine may help in detecting trophozoites (see Color 8). Flotation techniques with zinc sulfate may improve the accuracy of a

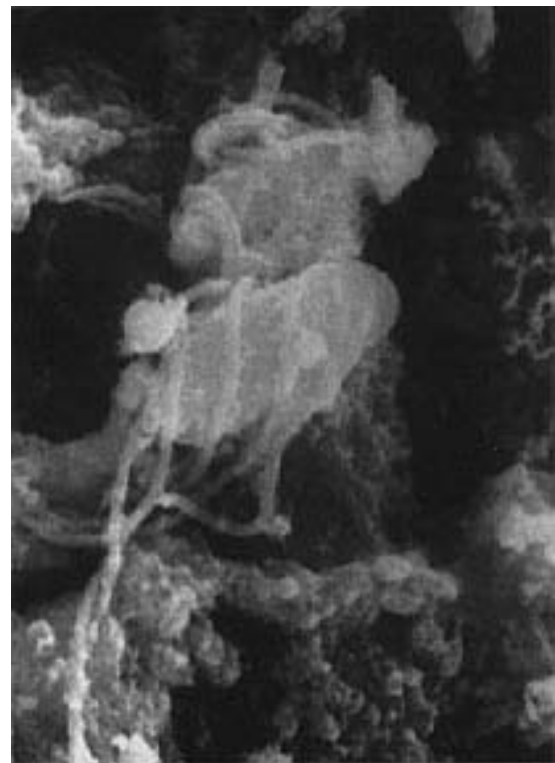

FIG 36.29 Electronmicroscopic view of giardia attached to the mucosal lining of the intestine (courtesy of Kenneth Latimer).

diagnosis. Trophozoites can range from 10 to 20 μm in length and 5 to 15 μm in width, depending on the host or type of fixation. The trophozoites have eight paired flagella (including an anterior and trailing posterior pair), two nuclei and a sucking disc that occupies most of the rounded end. The trophozoites attach to the surface of the villi in the small intestine. The sucking disc may be seen if the light is adjusted to maximize contrast. Cysts are believed to be intermittently shed in the feces, and multiple samples must be examined before considering that a bird is uninfected. The cysts measure 10-14 μm x 8-10 μm and contain four nuclei and fibrillar structures. ELISA tests have been developed to detect *Giardia* spp. in humans, but their efficacy for use in birds has not been evaluated.

Keeping the aviary as clean and dry as possible will reduce the viability and number of cysts available for transmission. Relapses are common after treatment either from endogenous parasites that are not destroyed or from reinfection from exposure to environmental reservoirs. Contaminated water supplies have been discussed as a method of repeated exposure of mammals to *Giardia* and may serve as a source of infection in birds. *Giardia* cysts survive the standard chlorination of water. *Giardia* appear to be limited in host range, and species isolated from birds have not been found to be infectious in mammals.

- **Hexamita:** *Hexamita* sp. has been detected in emaciated Splendid Grass Parakeets and cockatiels and can cause loose stool and weight loss.⁵¹ This genus has a trophozoite with eight flagella and two nuclei as does *Giardia*, but it lacks the sucking disc and is often truncated in appearance. Cysts are probably the infectious form. Generally, *Hexamita* is smaller than *Giardia*, swims in a smooth linear fashion and may be associated with chronic diarrhea. *Hexamita* has been described as a cause of disease in lorries. Demonstration of the parasite is common in asymptomatic pigeon feces and does not appear to cause a problem unless the birds are maintained in poor condition.
- **Histomonas:** Histomoniasis is common in gallinaceous birds. The induced disease is called blackhead and is caused by a flagellated protozoan parasite (*Histomonas meleagridis*) (see Color 20). In some birds, this parasite is considered a major pathogen while in other birds it is considered an incidental finding. When lesions occur, they generally include hepatomegaly (with necrosis) and ascites. Histomonads have also been described in the liver of several non-gallinaceous birds.

Most infections occur following the ingestion of infected embryonated eggs of the cecal worm *Heterakis gallinarum*. The histomonas are released from the larvae and invade the wall of the cecum where they may cause ulceration or small nodules. Parasites in the liver can cause severe hepatocellular necrosis.³⁰

Coccidia

Coccidian parasites include a variety of life styles and means of transmission. Oocysts of most genera are passed unsporulated. They are typically less than 45 μm in length, contain a granular-appearing spherical body (sporoblast) and may be round, ellipsoid or ovoid. There may be a thinning of the wall (the micropyle), and if the micropyle is present, it may have a cap. The wall may be smooth, mammillated or pitted and colorless to dark brown.

Coccidia are common in mynahs, toucans, pigeons, canaries, finches and lorries (Figures 36.24, 36.27). By comparison, infections are rare in captive Amazon parrots. Infections in mynahs and toucans rarely cause clinical changes unless the birds are maintained in crowded, unsanitary conditions. Clinical disease is occasionally seen in canaries and finches. Coccidiosis is a major cause of enteritis in Columbiformes and Galliformes.

- **Eimeria and Isospora:** Two species of *Eimeria* and one of *Isospora* have been described in psittacines (see Figure 36.24). *Eimeria dunsingi* oocysts are ovoid, lack a micropyle and are 26-39 x 22-28 μm . *E. haematodi* has broad ovoid oocysts with a large micropyle and measures 25-40 x 21-35 μm .¹⁰⁸ *Isospora psittaculacae* are round to broadly elliptical and measure 29-33 x 24-29 μm (see Figure 36.26). Sporulated oocysts of *Eimeria* are subdivided into four sporocysts each with two sporozoites, whereas with *Isospora*, the oocysts have two sporocysts each with four sporozoites. *Eimeria* and *Isospora* have direct life cycles. *Isospora canaria* completes its life cycle in the intestines. *E. dunsingi* has been discussed as being pathogenic, but support for this claim is lacking. In general, some cases of coccidiosis are associated with severe clinical disease, while other birds will pass numerous oocysts in the feces and remain asymptomatic.

Isospora is most common in Passeriformes, Psittaciformes and Piciformes, and *Eimeria* is most common in Galliformes and Columbiformes. Infected birds may be asymptomatic or develop clinical signs of melena, depression, diarrhea, anorexia and death. Direct transmission occurs through ingestion of fecal-contaminated food or water.

▪ ***Atoxoplasma*:** *Atoxoplasma* spp. may cause disease in canaries and other Passeriformes. Adults are generally asymptomatic carriers that shed oocysts in the feces. Prevalence can be high in young birds during fledging. The *Atoxoplasma* sp. found in House Sparrows was not found to be infectious to canaries, indicating a degree of host specificity.^{16,17}

Mortality can approach 80% in juvenile birds between two and nine months of age.²⁸ Clinical signs are nonspecific including depression, anorexia and diarrhea. Birds less than a year of age are most likely to develop clinical changes.^{36,85} Clinical signs may occur in birds that are or are not shedding oocysts in the feces. An enlarged liver and dilated bowel loops can occasionally be observed through the transparent skin (see Color 20). With severe infections, zoite forms of the parasite may be demonstrated in lymphocytes using Romanowsky staining methods (see Color 9).³⁶

Atoxoplasma serini has an asexual reproductive cycle in the mononuclear cells, and spreads through the blood to parenchymal organs where it infects reticuloendothelial and intestinal epithelial cells. *Atoxoplasma* spp. may be diagnosed by finding 20.1 x 19.2 µm oocysts in the feces or by demonstrating reddish intracytoplasmic inclusion bodies in mononuclear cells (Giemsa stain). Staining a buffy coat may improve the diagnostic sensitivity of blood smears. Transmission is direct through ingestion of contaminated feces. Canaries have been found to shed for eight months following infection.³⁶ Infected birds can intermittently shed large numbers of oocysts. Coccidial oocysts are environmentally stable and are not killed by most disinfectants.⁸⁵

In a group of infected canaries, atoxoplasmosis could be identified in impression smears of the heart, liver and pancreas using Giemsa stain. Atoxoplasmosis was the cause of death in two young Bali Mynahs. Oocysts were identified in the feces from young and adult birds in the affected group. Gross lesions in the mynahs included pinpoint white foci in the liver, splenomegaly, a swollen pale nodular pancreas and pericardial effusion (see Color 20).⁸⁵

No effective therapy for atoxoplasmosis has been described, but primaquine has been suggested to suppress the tissue form of the parasite, and sulfachlor-pyrazine may decrease oocyst shedding. *Atoxoplasma* infections may persist for over four months, while *Isoospora* infections are usually resolved within several weeks.³⁶

▪ ***Cryptosporidium*:** *Cryptosporidium* are spheroid-to-ovoid protozoa that infect and may cause disease in the mucosal epithelial cells lining the gastrointestinal, respiratory and urinary tracts of birds.^{3,42,67} *Cryptosporidium* develop intracellularly at an extracytoplasmic location on the apical surface of epithelial cells. This is in contrast to other coccidia, which replicate in the cytoplasm.⁷⁰ *Cryptosporidium* oocysts are the smallest of any coccidia, usually measure 4 to 8 µm in diameter and contain four naked sporozoites.

Cryptosporidiosis has been documented in Galliformes, Anseriformes, Psittaciformes, ostriches, canaries and finches (Table 36.4). Limited data suggest that cryptosporidial infections may be transmitted among closely related species, which should be considered when managing this coccidia in a collection. In the respiratory tract, *Cryptosporidium* may inhibit normal function of the mucociliary elevator, and have been associated with depression, anorexia, rhinitis, conjunctivitis, sinusitis, tracheitis, air sacculitis, coughing, sneezing and dyspnea in gallinaceous birds, ducks, geese and budgerigars. At necropsy, there may be an excessive amount of mucus in the respiratory tree.⁴²

TABLE 36.4 Location of Cryptosporidiosis Lesions by Species

	Respiratory Tract	GI Tract	Urinary Tract
Chickens	x	x	x
Ducks	x		
Turkeys	x	x	
Peafowl	x		
Pheasants	x		
Quail	x	x	
Junglefowl	x		x
Geese		x	
Psittaciformes		x	
Finches			x

In the GI tract, *Cryptosporidium* may infect the salivary glands, intestines, colon, cloaca and cloacal bursa, resulting in enteritis (diarrhea) in gallinaceous birds, Amazon parrots, budgerigars, macaws, cockatiels, lovebirds and cockatoos.^{10,29,42} Postmortem findings with gastrointestinal cryptosporidiosis may include dilated intestines containing yellowish fluid and blunting fusion and atrophy of intestinal villi.¹⁰ Cryptosporidiosis caused cuboidal metaplasia of glandular epithelium in the proventriculus in a finch that died following an acute onset of diarrhea.¹³ Proventricular lesions have also been described in in-

ected canaries.¹⁰⁷ Cryptosporidial renal disease has been described in gallinaceous birds and finches. The kidneys of both birds were enlarged and pale.^{42,68}

In some cases *Cryptosporidium* is considered a primary pathogen; however, in most situations it is considered to cause severe infections only in immunocompromised hosts. Suggestive of the opportunistic nature of *Cryptosporidium* was the detection of the parasite in four cockatoos with PBFV virus. In three birds, the parasite remained localized to the epithelium of the cloacal bursa. In the other bird, *Cryptosporidium* was present throughout the large intestines, small intestines and bursa (see Figure 32.16).⁶⁵

Cryptosporidium sp. was identified by Sheather's flotation in 14 of 165 (8.5%) adult ostriches in a quarantine station. The number of parasites varied from a few to several million per gram of feces. There were no clinical signs in any of the birds in which *Cryptosporidium* was identified. *Cryptosporidium* recovered from the ostriches was not infectious to two-day-old chickens inoculated orally. None of the birds in this study had clinical signs of infection, but the possibility exists that *Cryptosporidium* could cause problems in young or immunocompromised birds.³⁹

This coccidian parasite can be transmitted through the ingestion or inhalation of sporulated oocysts. The life cycle is direct. *Cryptosporidium* undergoes endogenous sporulation resulting in autoinfection in the parasitized host. As few as 100 oocysts can induce severe enteritis and diarrhea in experimentally infected Bobwhite Quail in the company of reovirus.⁵⁰

Cryptosporidium spp. are sporulated when shed in the feces so the frequent cleaning regimes that are used to control other coccidia are ineffective in preventing exposure to cryptosporidial oocysts. *Cryptosporidium* is resistant to many disinfectants. Formal saline (10%), ammonia (5%) and heating to 65°C for 30 minutes have been suggested as effective control measures for *Cryptosporidium*.¹⁰⁵

The small size of the organism (4 to 6 µm) and low shedding rate make diagnosis of infection difficult. Diagnosis can be improved by centrifuging diluted feces in a high-concentration salt solution or using Sheather's flotation. Fecal smears stained with Giemsa, carbofuschin or PASchift stains may be used to demonstrate oocysts. With modified acid-fast stain, *Cryptosporidium* stains pink against a blue background. *Cryptosporidium* oocysts were identi-

fied in the feces of budgerigars, parrots and macaws using Auramine O.⁶⁶

Cryptosporidium spp. that infect birds are different from the species that infect mammals and there is no known zoonotic potential.

- **Toxoplasma:** *Toxoplasma* is a coccidian parasite with an indirect life cycle. Toxoplasmosis, causing fatal infections in most species, has been documented in the Red Lory, Swainson's Lorikeet, Regent Parrot, Superb Parrot and Crimson Rosella.^{52,57} *Toxoplasma gondii* is considered a ubiquitous organism with a broad host range, and probably could infect any mammalian or avian host. Oocysts produced and passed in the feces of infected cats would be the only source of infection to psittacine birds. Infections may cause congestion and consolidation of the lungs, hepatomegaly, vasculitis and necrotic foci in the lungs, liver and heart.⁵⁷
- **Sarcocystis:** *Sarcocystis* is a coccidian parasite that undergoes sexual multiplication in the intestine of a definitive host. *Sarcocystis falcatula* appears to be restricted to North America and has been associated with acute deaths in a variety of psittacine species. The pathogenicity of sarcocystosis in psittacine birds appears to depend on the species of bird and the infective dose of the parasite.¹⁸ Severe life-threatening infections are most common in Old World Psittaciformes although neonates of New World species may also die following infection. Adult New World Psittaciformes appear to be relatively resistant (Table 36.5). The susceptibility of Old World Psittaciformes and resistance of New World Psittaciformes may reflect a lack of immunity in the former because the definitive host (and presumably the parasite) are not found in the Old World. Infections appear to be more common in the winter months and males appear to be more susceptible than females. There is no apparent age resistance and a bird over 33 years of age died in one outbreak.^{23,24,56,82}

TABLE 36.5 Psittacines Confirmed Susceptible to Sarcocystis

African Grey Parrot	Military Macaw
Amazon parrots	Pesquet's Parrot
Blue and Gold Macaw	Port Lincoln Parrot
Budgerigar	Princess Parrot
Cockatiel	Red-capped Parrot
Cockatoo	Red Shining Parrot
Conures (Halfmoon, Patagonian)	Thick-billed Parrot
Eclectus Parrot	White-crowned Pionus
Great-billed Parrot	Tori Parakeet
Green Rosella	
Lories (Red)	

TABLE 36.6 Blood Parasites

Blood Parasite	Location	Some Susceptible Species	Intermediate Host	Clinical Changes
<i>Haemoproteus</i>	Gametocyte in erythrocytes, schizonts in endothelial cells	Anseriformes, Passeriformes, raptors, cockatoos, Columbiformes	Culicoides, louse flies	Rare; anemia (severe infections), reduced stamina in pigeons
Microfilaria	Adults in air sacs, fascial planes, tendon sheaths, pericardial sac	Psittaciformes, raptors	Culicoides, black flies, some lice, mosquitoes	Generally apathogenic, adults (tendinitis in Amazons), Pericarditis in cockatoos, Asphyxiation from occluded capillaries
<i>Trypanosomes</i>	Extracellular in blood	Passeriformes (esp. canaries), Galliformes, Anseriformes, Columbiformes, some Psittaciformes	Louse flies, mosquitoes, black flies	Minimal pathogenicity
<i>Leucocytozoon</i>	Gametocytes in leukocytes or red blood cells	Anseriformes, Galliformes, Passeriformes, Psittaciformes	Black flies, <i>Culicoides</i>	Anemia, dyspnea, death (with some species)
<i>Plasmodium</i>	Gametocytes, trophozoites, schizonts in erythrocytes or its precursors	canaries, penguins, Galliformes, Anseriformes, Columbiformes, Psittaciformes Passeriformes (carriers)	 Mosquitoes	Anemia, dyspnea, weakness, anorexia, death Asymptomatic, vomiting, anorexia, depression
<i>Atoxoplasma</i>	Sporozoites in lymphocytes and monocytes; schizonts, oocysts, gametocytes in internal organs	Passeriformes	None	Depression, hepatomegaly, diarrhea
<i>Babesia</i>	Erythrocytes		Ticks	Non-pathogenic

Infections are usually peracute; birds may appear normal and healthy one day and be dead the next. Experimentally infected cockatoos were found to die 10 to 14 days after oral inoculation. If clinical signs occur prior to death, they are characterized by severe dyspnea, yellow-pigmented urates and lethargy. Infected birds have been found to have high LDH and AST enzyme activities.^{23,24}

Pulmonary edema with hemorrhage is the most consistent sign in birds that die acutely (see Color 22). Splenomegaly and hepatomegaly also are common (see Color 14). Histopathologic findings include diffuse interstitial and exudative pneumonia, reticuloendothelial cell hyperplasia and schizonts or merozoites in the capillary endothelium. The lung is the tissue of choice for diagnosis where schizonts may be noted.^{24,58} Rarely, schizonts may be identified in the brain of birds with CNS signs.^{56,59} Generally, psittacine birds die before sarcocysts develop in the muscles.

The two-host replication cycle of *S. falcatula* involves sexual reproduction and sporogony in the intestines of the definitive host (opossum) with passage of infectious sporulated oocysts or sporocysts in the feces. Following ingestion of the sporocysts, asexual repro-

duction with schizogony and sarcocyst formation occur in the intermediate host (psittacine birds).¹⁰¹ The ingested sporozoites invade intestinal mucosa followed by infection of numerous tissues and schizogony in the reticuloendothelial cells, particularly in the lungs. Asexual reproduction then occurs in the walls of arterioles (first cycle) and capillary and venule walls (second cycle). These replication cycles can cause occlusion of the affected vessels resulting in the fatal lesions characteristic of infections in Old World Psittaciformes.

In a normal infectivity cycle, the intermediate host survives schizogony in the vascular endothelium and mature cysts containing bradyzoites are subsequently formed in striated (skeletal or cardiac) muscles. In Old World Psittaciformes, infections usually cause fatal vascular changes before cysts are formed. Schizogony in the vascular endothelium of experimentally infected budgerigars was found to cause death by occlusion of the vessels secondary to endothelial hypertrophy, schizont formation and endophlebitis.

In adult New World Psittaciformes, the merozoites produced through asexual reproduction are trans-

ported via the circulatory system to striated muscles where they undergo further reproduction in sarcocysts (270 x 37 µm). Old World psittacines that survive schizogony in the endothelium of the lungs have been found to develop cysts ten weeks post-infection.¹⁸ *Sarcocystis* also infects Passeriformes and Columbiformes, where cockroaches and flies can serve as transport hosts.

Psittacine birds in outdoor facilities throughout the range of the opossum are at risk. Infected opossums can shed sporocysts in the feces for 100 days. Cockroaches can serve as transport hosts by eating infected opossum feces and being consumed by susceptible birds.^{24,56,100} Prevention requires fencing to prevent access of opossums to the aviary. Flightless chickens have been suggested as a method of controlling cockroaches within a compound (see Chapter 2).

Sarcocystis was responsible for the deaths of 37 Old World Psittaciformes in a zoologic collection over a 15-month period. Lories, cockatoos, Pesquet's Parrot, Port Lincoln Parrot, lorikeets, Princess Parrot and rosellas were included in the affected group. About half of the birds developed clinical signs prior to death, while the other birds died with no premonitory signs. When clinical signs occurred, they included anorexia, diarrhea, weakness, tachypnea, ataxia, posterior paresis, head tilt and dyspnea prior to death. Some birds had clinical signs that lasted several hours while others had clinical signs that progressed over a 52-day period. Characteristic necropsy findings included pulmonary hemorrhage, spleno-megaly and hepatomegaly.⁵⁶

In a zoologic collection, five Eclectus Parrots and four Hispaniolan Amazon Parrots were diagnosed with sarcocystosis over a six-month period. Four of the Eclectus and two of the Amazon parrots died. Elevations in CPK, AST and LDH enzyme activities were noted in all the affected birds. Clinical signs included weakness, dyspnea and blood in the oral cavity. Affected birds died one to 36 hours after presentation. Radiographic findings indicated an increased lung field density, hepatomegaly, splenomegaly and renomegaly. Some birds that were only slightly lethargic and had no other clinical signs survived following treatment with 0.5 mg/kg pyrimethanamine PO BID and 30 mg/kg trimethoprim-sulfadiazine IM BID for 30 days. The surviving birds responded to therapy with improved attitude, appetite and decreased serum enzyme activity. Muscle biopsies after treatment revealed multifocal myositis and sarcocysts, indicat-

ing that the birds had survived the schizogony phase of the infection allowing muscle cysts to form.⁸¹

Encephalitozoon sp. is a microsporidian parasite with a broad host range that includes mammals and birds. This parasite has complex spores measuring 1.5 x 1.0 µm and containing a coiled polar filament. The latter will be seen only with the aid of electron microscopy. Lovebirds of the genus *Agapornis* are frequently infected,⁹³ but an Amazon parrot with a microsporidian infection has also been reported.^{69,90} The spores were documented in kidney tubules, lung, liver and the lamina propria of the small intestine.^{69,89}

Few birds have been reported with this parasite and all cases were detected at necropsy. One report gave the details of a die-off of 140 lovebirds in Great Britain in which the birds were moved to a different facility, stopped eating and lost condition.

An infected Amazon parrot developed progressive anorexia, weight loss, respiratory disease and diarrhea over a one-month period. Postmortem findings included pale, swollen kidneys and an enlarged, mottled liver. Kidney tubular epithelial cells were filled with tiny spores, as were epithelial cells in the liver and small intestine. Histologic changes were characterized by multifocal nephritis, hepatitis and enteritis.

Hemoparasites

Haemosporidian parasites have been detected in parrots being imported into England and Japan.^{78,86,88} *Haemoproteus* was commonly seen in imported Psittaciformes^{12,96} and *Haemoproteus* and *Leucocytozoon* were detected in free-ranging birds in southeast Asia.⁷¹ It is unknown what role, if any, that flies indigenous to North America could play in transmitting the species of *Haemoproteus* or *Leucocytozoon* that occur in birds from other geographic regions. The sexual phase and a form of asexual reproduction occur in biting flies, resulting in the production of sporozoites that localize in the salivary glands and are inoculated into the avian host. Asexual reproduction also occurs in an infected bird.

- ***Haemoproteus*:** Under normal circumstances, species of *Haemoproteus* are considered nonpathogenic and a few species of *Leucocytozoon* and *Plasmodium* are considered pathogenic. If clinical signs occur, they are associated with anemia, splenomegaly, hepatomegaly and pulmonary edema. The lymphoid-macrophage system becomes hyperplastic. High parasitemias of a pathogenic *Haemoproteus* and *Leucocytozoon* can cause clinical problems if a bird is stressed or immunosuppressed. Racing pigeons in-

ected with *H. columbae* are frequently discussed as performing poorly in comparison to uninfected birds.

Haemoproteus spp. are the most commonly occurring avian blood parasite; they use *Culicoides* (biting midges or punkies) or louse flies as vectors. In some studies, up to 50% of recently imported cockatoos were found to be positive. In contrast, only 5% of long-term captive cockatoos were found to have *Haemoproteus*.²⁵ In a survey of 81 African Grey Parrots, 5.7 % had *Haemoproteus*.⁹⁶ Most infected birds are subclinical but severe infections in stressed birds may lead to life-threatening anemia. Infections may be potentiated by concurrent disease or stress.

H. handai gametocytes completely encircle the red blood cell nucleus.¹² Initial parasite development occurs in endothelial or skeletal muscle cells followed by the production of pigmented gametocytes in RBCs (see Color 9). Some European dieoffs of psittacine birds that were attributed to *Leucocytozoon* were probably caused by *Haemoproteus*. In Roseate Parakeets infected with sporozoites of *H. handai*, large schizonts developed in the skeletal muscles.⁷³ In another study with *H. meleagridis* in turkeys, it was demonstrated that development of large schizonts occurred following inoculation of sporozoites.⁵

- **Leucocytozoon:** *Leucocytozoon* spp. use Simuliidae (black flies) as vectors. Initial development occurs in the liver and spleen followed by the development of unpigmented gametocytes in white blood cells or RBCs, depending upon the species (see Color 9). Infected host cells are distorted beyond recognition. Although there have been occasional reports of *Leucocytozoon* on blood films taken from psittacine birds, much of the emphasis on this genus in the European literature is based on finding megaloschizonts in muscles of birds that have presumably died as a result of the infection.^{41,103} No one has reported blood stages that are more definitive for generic identification, although the birds may have died prior to the development of gametocytes. These deaths probably resulted due to infections of *Haemoproteus*, not *Leucocytozoon*.

Leucocytozoon has a seasonal incidence in the wild with parasitemia being highest in the spring. Following infection, high numbers of the parasite may be detected in the blood within four to nine days. The parasite produces an anti-erythrocytic factor, which causes intravascular hemolysis and anemia, the principal clinical sign. *Leucocytozoon* is highly pathogenic in young Anseriformes and Galliformes.⁴⁵ Fatal infections have been described in budgerigars. Hepa-

tomegaly, splenomegaly, pulmonary congestion and pericardial effusion are the most characteristic gross findings. Pyrimethamine has been suggested for treatment.

- **Plasmodium:** *Plasmodium* spp. use mosquitoes as vectors. Initial parasite development occurs in the avian reticuloendothelial system followed by the development of pigmented schizonts and gametocytes in the erythrocytes (RBCs) (see Color 9). Schizogony occurs in the erythrocytes, which means that blood-to-blood transfer, without an intermediate host, can result in an infection.

Plasmodium spp. have been described in a number of companion and aviary birds. Species of *Plasmodium* are most likely to occur in an avicultural setting because it has the widest host range of all the haemosporidian parasites. Apathogenic strains of *Plasmodium* may cause asymptomatic infections in cockatoos and passerine birds. Some Passeriformes serve as asymptomatic carriers. Some strains of *Plasmodium* are highly pathogenic in canaries, penguins, Galliformes, Anseriformes, Columbiformes and falcons. Clinical signs are most common in recently infected birds and are characterized by anorexia, depression, vomiting and dyspnea for a few hours or days prior to death. In penguins, depression, anemia, vomiting, seizures and high levels of mortality may be noted.³⁴ Nonpathogenic strains of *Plasmodium* have also been described in many of these same avian orders.

Six species of *Plasmodium* and one of *Haemoproteus* have been reported from Psittacidae.¹¹ *P. relictum* is a large species that is round as both gametocytes and schizonts (8 to 24 merozoites) and displaces the RBC nucleus toward the pole. *P. nucleophilum* is a small form with elongate, amoeboid gametocytes, which along with small schizonts (4 to 8 merozoites), tightly adhere to the RBC nucleus. *P. vaughani* is another small species with amoeboid gametocytes; the merozoites (4 to 8 per schizont) of schizonts appear to lack cytoplasm, and neither stage clings to the RBC nucleus. *P. dissanaike* has larger elongate gametocytes that fill the lateral cytoplasm of the RBC and its small schizonts (4 to 12 merozoites) may adhere to the RBC nucleus. *P. circumflexum* has large halter gametocytes that usually wrap around the ends of the host cell nucleus and fill most of the RBC cytoplasm. Its schizonts are larger than the RBC nucleus and contain 6 to 30 merozoites, which are arranged in a halter around the RBC nucleus. *P. polare* has variable gametocytes, but they often are

halteridial or at least the length of the RBC. The schizonts are usually in a polar position and are irregular, round or fan-shaped with 8 to 14 merozoites.

- **Trypanosoma:** *Trypanosoma johnbakeri* is an extracellular, flagellated blood parasite that is transmitted by a biting midge and has been demonstrated in Roseate Parakeets, but has not been associated with clinical signs.⁷⁴ In one study, trypanosomes were identified in 14% of imported Hyacinth Macaws, and 20% of imported Green-winged Macaws examined.²⁵

Helminths

Flatworms

Flatworms include digenetic flukes and tapeworms. Flukes found in psittacine birds may reside in the liver (*Platynosomum*, *Lyperosomum*, *Dicrocoelium* and *Brachylecithum*) or in the blood vasculature (a schistosome believed to be *Gigantobilharzia*). Tapeworms live in the small intestine (*Triuterina*, *Biporouterina*, *Cotugnia* and *Raillietina*).

- **Flukes:** Flukes living in the bile ducts are members of the family Dicrocoelidae. All of the cases reported in North America have probably occurred in imported birds (Old World species) that were infected by endemic species in their country of origin. Birds may be infected by eating an arthropod, which serves as a second intermediate host. Liver flukes have rarely been demonstrated in New World Psittaciformes, even though there are a number of genera that occur in North American avifauna. Clinical changes associated with liver fluke infections include hepatomegaly, depression, anorexia, mild anemia, weight loss, diarrhea, hepatic necrosis, elevated liver enzymes and death.^{61,64,92} There is a single case reported of a schistosome in a Nanday Conure that died after showing weight loss, anorexia and blood-tinged diarrhea.⁴⁸ Histologic evidence of colitis and cloacitis was present along with an epithelial hyperplasia of the lower gut.

Hepatic trematodiasis has been reported in cockatoos. Numerous trematode eggs were seen on direct smears of the feces. Necropsy findings were primarily limited to the liver and were characterized by hepatomegaly, increased firmness, numerous streaks, brown and yellow mottling and fibrosis. In some birds, trematodes were found in dilated bile ducts. Histologic lesions were characterized by hepatic fibrosis and bile duct hyperplasia. Clinical improvement following treatment with fenbendazole and praziquantel was minimal; however, the number

of eggs per gram of feces did decrease dramatically following therapy.⁹² Biliary cholestasis and cystic dilatation have also been described in birds with trematodiasis.⁷⁷ Schistomiasis can cause heavy motility in free-ranging Anseriformes.^{111,112}

- **Tapeworms:** Tapeworms infecting psittacine birds^{27,72} can be asymptomatic or the parasite may steal nutrients from the host causing a bird to appear unthrifty and have diarrhea (see Figure 36.28). Infections are most common in finches, African Grey Parrots (15 to 20% of imported birds), cockatoos (10 to 20% of imported birds) and Eclectus Parrots.^{22,95} Infections occasionally occur in South American Psittaciformes. Eosinophilia has been discussed as a clinical change associated with tapeworm infections. However, there has been no direct relationship demonstrated between parasitism and eosinophilia in birds. In general, infections are nonpathogenic although large numbers of worms can cause impaction. With severe infections, birds may die following a period of weight loss and diarrhea.

Tapeworms require intermediate hosts, and infections are uncommon in birds that do not have access to the ground. Either proglottids or whole worms may be noted in the feces. Eggs of *Triuterina* and *Biporouterina* are single whereas those of *Raillietina* and *Cotugnia* are passed in clusters encased in a mucilaginous material. Focusing through the individual rounded eggs to see the hooks on the hexacanth larva may be necessary to demonstrate that these are tapeworm eggs. Infections may not be detected during routine fecal exams unless a proglottid present in the feces has ruptured. The eggs contain six hooks on oncosphere and hexacanth larvae.

Roundworms

Roundworms (nematodes) are more diversified than flatworms and live in the small intestine (*Ascaridia*, *Ascarops* and *Capillaria*), proventriculus and ventriculus (*Microtetrameres*, *Procyrnea* and *Ascarops*),^{33,37} the surface of the eye (*Thelazia*, *Oxyspirura*, *Ceratospira* and *Annulospira*) and in subcutaneous regions, body cavity and air sacs (*Eulimdana*, *Pelecitus*, *Cardiofilaria* and *Cyathospira*).

- **Ascarids:** Ascarids are the most common parasite found in birds that are maintained in enclosures with access to ground. Infections are particularly common in budgerigars and cockatiels. Species that infect psittacine birds include *Ascaridia columbae* (shared with pigeons), *A. galli* (shared with gallinaceous birds)⁸⁷ and *A. platycerci*,⁷⁶ which is restricted thus

far to Psittaciformes. While there are other species described, their validity is questionable.^{53,75,76}

The direct life cycle requires a two- to three-week period for embryonated larva to form within the egg, which is viable for extended periods in moist warm environments. The eggs are resistant to disinfectants but can be controlled with steam or flaming. The ingested larvae infect the intestinal mucosa. Mild infections can cause malabsorption, weight loss, anorexia, growth abnormalities and diarrhea. Heavier parasite loads may cause intussusception, bowel occlusion or death (Figure 36.30).

Providing a dry clean environment will decrease the possibility that eggs will survive to embryonate. Piperazine, pyrantel pamoate and fenbendazole may be effective in resolving infections.

Cerebrospinal nematodiasis caused by larvae from *Baylisascaris procyonis* (raccoon ascarids) has been reported in gallinaceous birds, cockatiels, ratites and several Passeriformes.^{4,80} Infective eggs are ingested by the bird; the larvae are digested free from their eggs, where they penetrate the intestinal wall and begin migrating through the tissues. They do not mature and continue to migrate in a form of visceral larval migrans. When they enter the central nervous system, the larvae induce considerable damage leading to ataxia, torticollis, depression and death.⁴

In a group of mixed macaws, seven of ten potentially exposed birds developed ataxia, torticollis and depression after being placed in contact with raccoons. *B. procyonis* larvae were identified in the cerebrospinal tissue of 6 of the birds. The earliest clinical signs developed 35 days after potential exposure to the raccoons. Other birds developed clinical signs over a nine-month period. Some birds developed lesions 7.5 months after being removed from any exposure to the parasite.²² An ostrich and two emus developed progressive ataxia (two to three weeks) and eventually died. Necropsy findings included multifocal encephalomalacia of the brain stem and cerebellum caused by *Baylisascaris* larvae. Infective eggs were recovered from the ground of the ostrich pen.^{62,63}

Because no diagnostic stages of the parasite are released to the environment, and no commercially available serological diagnostic kit is available, this parasite is normally diagnosed histologically at necropsy. The best means of control is to prevent access of free-ranging raccoons to aviaries, and thus prevent contamination of the environment by these thick-walled and long-lived eggs.

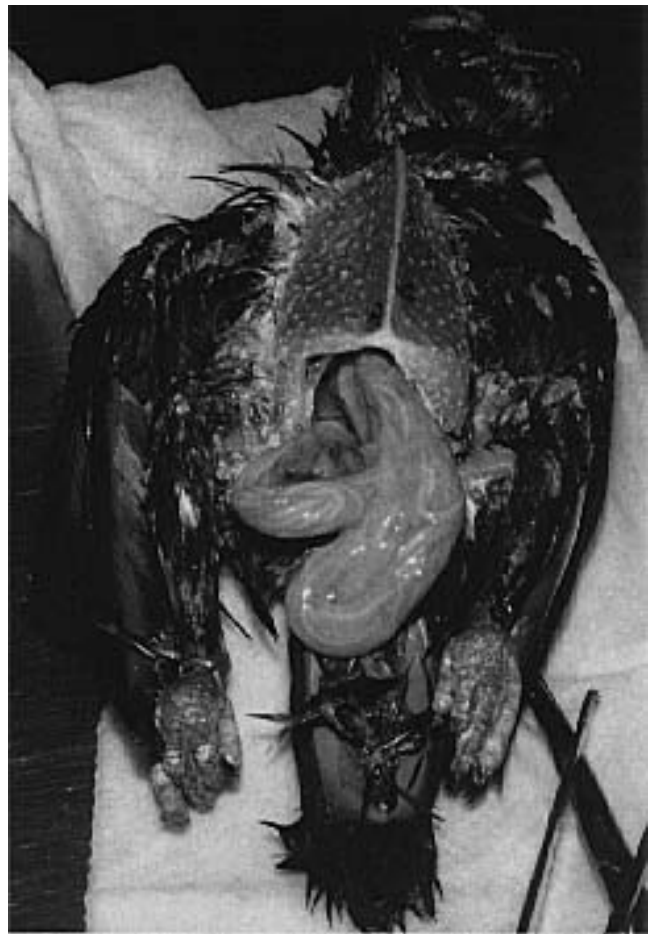

FIG 36.30 A two-year-old Severe Macaw was presented with vomiting, diarrhea and chronic weight loss, even though the bird had a voracious appetite. The bird had lost most of its pectoral muscle mass (weight 230 g), and had a distended abdomen. Radiographs indicated enlarged bowel loops, diffusely filled with linear soft tissue densities. A fecal exam revealed thousands of ascarid eggs. The bird did not respond to supportive care. This bird was maintained in a mixed species outdoor exhibit with access to the ground. Intestinal nematodes are rare in companion birds maintained indoors and in aviary birds maintained in suspended enclosures.

Ascarids in the genus *Heterakis* can infect the ceca of gallinaceous birds, Anseriformes and other birds. Nodular lesions consisting of fibrotic and granuloma-

tous tissue may develop in the submucosa of the ceca, particularly in pheasants (see Color 14). The life cycle is direct following ingestion of embryonated ova. In some species (quail), infections are subclinical, while other affected birds can die from complications associated with the mucosal and submucosal lesions.

- **Capillaria:** Species of *Capillaria* are tiny thread-like nematodes that may infect the gastrointestinal tract of most species of companion and aviary birds.^{22,109} Infections appear to be most common in macaws, budgerigars, canaries, pigeons and gallinaceous birds. Severe infections can cause diarrhea (which may contain blood), weight loss, anorexia, vomiting and anemia.²² Little has been published on these worms as to the species present or their true influence on these birds; the clinical effects are not severe. Species of this genus in other birds are profound pathogens when they reside in the upper digestive tract, particularly in gallinaceous birds. The life cycle of *Capillaria* is direct.

Embryonation requires approximately two weeks, and eggs can remain infectious in the environment for several months. The adults can burrow into the mucosa of the esophagus, crop or intestinal tract causing depression, dysphagia, regurgitation, diarrhea, melena and weight loss. *Capillaria* that infect the crop, esophagus and oral cavity burrow into the mucosa, creating tracts that may fill with blood, producing hyperemic streaks. Frank hemorrhage may occur in the upper intestinal tract in heavily parasitized animals. Diphtheritic lesions may occur in the mouth, pharynx, esophagus and crop of some infected species.

Scrapings of suspect lesions or fecal flotation can be used to detect the characteristic bipolar eggs (see Figure 36.18). Magnification may be necessary to see the adults.

- **Spiruroidea:** The superfamily Spiruroidea represents the most diversified group of nematodes in birds. Little on the biology and pathology of these nematodes is known, but the life cycle probably involves an insect intermediate host. *Ascarops* sp. has been recovered from the intestines of a Greater Sulphur-crested Cockatoo and *A. psittaculai* was described in a Rose-ringed Parakeet.^{102,110} *Procyrnea kea* was described from the New Zealand Kea where it lives under the koilin of the ventriculus.²⁰ *Microtetratmeres nestoris* was found in the proventriculus of the North Island Kaka where it caused hyperplasia

and metaplasia of the duct epithelium, glandular atrophy and limited necrosis and hemorrhage.²¹

Four genera of eyeworms (*Thelazia* and *Ceratospira*) have been reported (see Color 26).^{2,19,66,106} The intermediate host is considered to be the fly. Eyelid spasms and mild conjunctival hyperemia were evident in a Senegal Parrot with *Thelazia* even though only three adults were recovered. The worms were removed after they were incapacitated with 0.125% demecarium bromide.¹⁹ In contrast, no pathology was associated with numerous *Ceratospira* infecting a Moluccan Cockatoo. *Thelazia digitata* has been recovered from the eye of several macaws.² *Annulospira* has been removed from the eye orbits of a Rose-ringed Parakeet.⁶⁰

Oxyspirura sp. is common in the eye of cockatoos where it resides beneath the nictitating membrane or in the conjunctival sac. Severe infections may cause conjunctivitis, chemosis and scratching at the eye. The eyelids may close due to the accumulation of caseous debris. The parasite has an indirect life cycle that involves an arthropod (cockroach) intermediate host. Ivermectin can be used to kill the worms, which are then removed by flushing.

Streptocara spp. are pathogenic spiruroids that burrow into the mucosa of the esophagus, crop, proventriculus and ventriculus, principally in Anseriformes. Crustaceans serve as an intermediate host. In severe infections, diaphoretic esophagitis or gastritis associated with ulceration and frank hemorrhage may occur.

Spiroptera incerta and *Dispharynx nasuta* have been reported in association with thickening of the proventricular mucosa in a number of Psittaciformes (see Color 19). The adult worms burrow into the proventriculus causing ulcers, inflammation and nodule formation. The proliferative mucosa may prevent the passage of ingesta resulting in chronic vomiting and weight loss (Figure 36.31).

A large-mouthed worm (*Cyathostoma cacatua*) related to gapeworms has been reported from the air sacs of a Sulphur-crested Cockatoo.¹⁴ Lungs from infected birds were consolidated, had extensive necrosis and caseation and contained bacteria and many parasite eggs.

- **Syngamus:** *Syngamus trachea* (gapeworm) has been diagnosed in many species of companion and aviary birds. Infections are rare in companion birds but are common in Galliformes and Anseriformes (Figure 36.32). The red Y-shaped adult parasite can be visu-

alized on the mucosa of the trachea and primary bronchi. Adult birds are generally resistant and most infections occur in young birds. Coughing, open-mouthed breathing, dried blood at the beak commissure, dyspnea and head shaking are common. With severe infections, death can occur secondary to tracheal ulceration, anemia and asphyxiation. The eggs of the parasite can be detected in the feces. The life cycle is direct but earthworms can serve as a transport host. Thiabendazole has been recommended for treatment. Ivermectin can be used to kill the parasites and they can be mechanically removed by repeated transtracheal washes.

- **Filariidea:** The filariid nematodes have indirect life cycles and are transmitted to birds by blood-feeding diptera. A recent key to the genera of adult filarial worms has been published.⁷ The diagnostic stage of these worms is the microfilaria and in most cases, the microfilariae have not been matched to the adults. The adults live in the body cavity, chambers of the eyes, heart or air sacs (Figure 36.33). Species of *Pelecitus*, *Chandlerella*, *Cardiofilaria* and *Eulimdana* occur in psittacine birds. Adult *Pelecitus* reside in subcutaneous tissues causing masses, typically on the legs and feet.^{1,47} A taxonomic revision of the genus *Pelecitus* has been made.⁸ Other filariae have been documented in psittacines, but nothing has been discussed about known or potential pathogenesis.^{9,26}

Microfilariae were at one time considered common in the peripheral blood of Passeriformes and Psittaciformes with the incidence in imported cockatoos being particularly high (up to 45%). By comparison, only six percent of imported non-cockatoo psittacine birds were found to have microfilariae in one study.²⁵ Many cockatoos with microfilariae are also found to be infected with *Haemoproteus*. Microfilariae are easiest to detect by examining the buffy coat on a hematocrit tube. Microfilariae exhibit periodicity and several blood tests may be necessary to demonstrate the parasites.

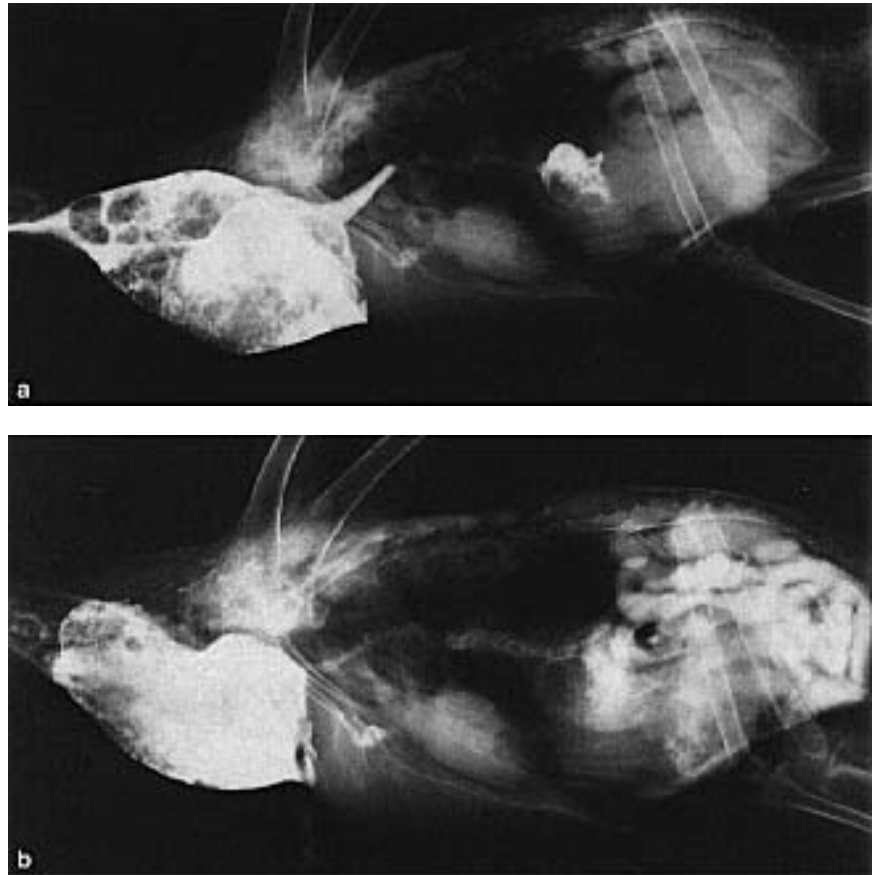


FIG 36.31 A mature Umbrella Cockatoo was presented with a history of progressive weight loss of one month's duration. The bird had been vomiting for a week before presentation. Survey radiographs indicated a thickened proventriculus. Contrast medium was instilled into the crop and indicated a thickened proventricular mucosa and slowed gastric emptying time: **a**) at 20 minutes; **b**) at six hours. Note the small heart (suggestive of severe dehydration) and microhepatia. The client chose euthanasia. At necropsy, the proventricular mucosa was ulcerated and inflamed and had numerous nodules. *Spiroptera* eggs were identified in proventricular washings.

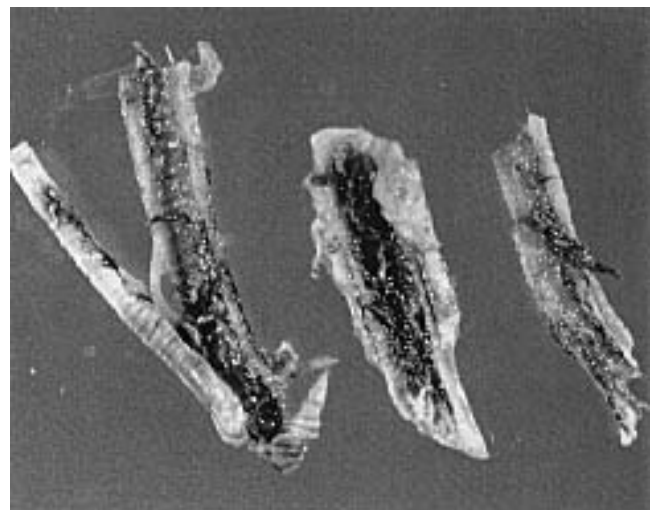


FIG 36.32 *Syngamus* spp. are seen in the trachea of a duck. Note the hemorrhage and accumulation of necrotic debris associated with the parasites (courtesy of Robert Schmidt).

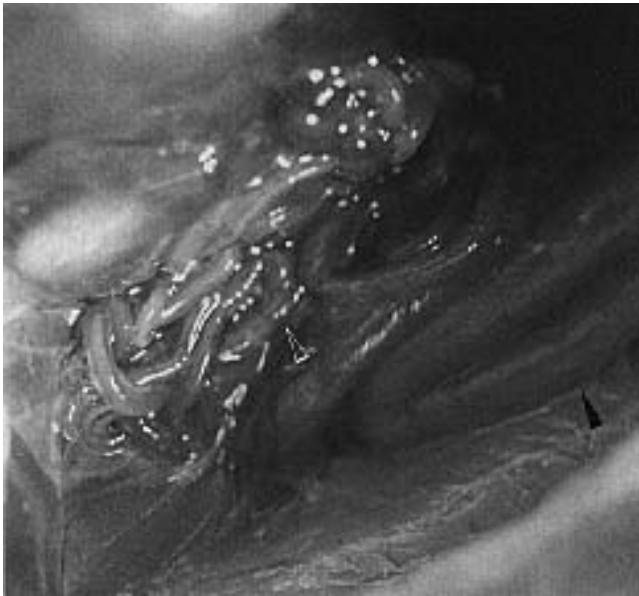


FIG 36.33 Uncharacterized filariid nematodes (open arrow) were found in the air sacs of a free-ranging Barn Owl that died from a gunshot wound. The air sacs were clear and appeared to be unaffected by the parasites. A loop of bowel (arrow) is also evident.

The adults primarily inhabit the air sacs but may also occur in the joints, subcutaneous tissue and pericardial sac. In most situations, the adults and microfilariae are considered apathogenic; however, filarial worms in the joints and subcutaneous tissues can cause severe problems and should be removed (Figure 36.34).

Adult filarial worms filling the pericardial sac of a Red-vented Cockatoo caused death.²² An Umbrella Cockatoo with a one-week history of anorexia, ataxia, diarrhea and increased vocalization was found at necropsy to have microfilariae in the small vessels of the brain, lungs, kidneys, spleen, heart and liver. Adult filariae were identified in the vena cava.⁵⁵ Adult filariae were found in the heart of a recently imported Ducorp's Cockatoo with PBF (see Color 14).

Arthropods

Hematophagous diptera including mosquitoes, black flies and biting midges can feed on psittacine birds and transmit blood parasites. Direct effects of these parasites may include anemia, which is particularly common in neonates during the rainy season in South Florida (see Color 24).

Biting lice known to occur on psittacines include *Neopsittaconirmus*, *Psittaconirmus*, *Eomenopon* and *Pacifimenopon*. Lice may cause pruritus and poor feather condition. The parasites can be observed directly, or the nits (eggs) can be seen attached to the feathers (see Figure 48.21). Most species are host specific and die quickly when they leave a host. Dusting with pyrethrin can control infections. Because many of the parrots and their relatives have not been examined for lice, there are probably many more species that have not been characterized.^{90,91}

- **Mites and Fleas:** Numerous mites have been detected on and in psittacine birds. The scaly leg and face mite, *Knemidokoptes pilae*, is the most fre-

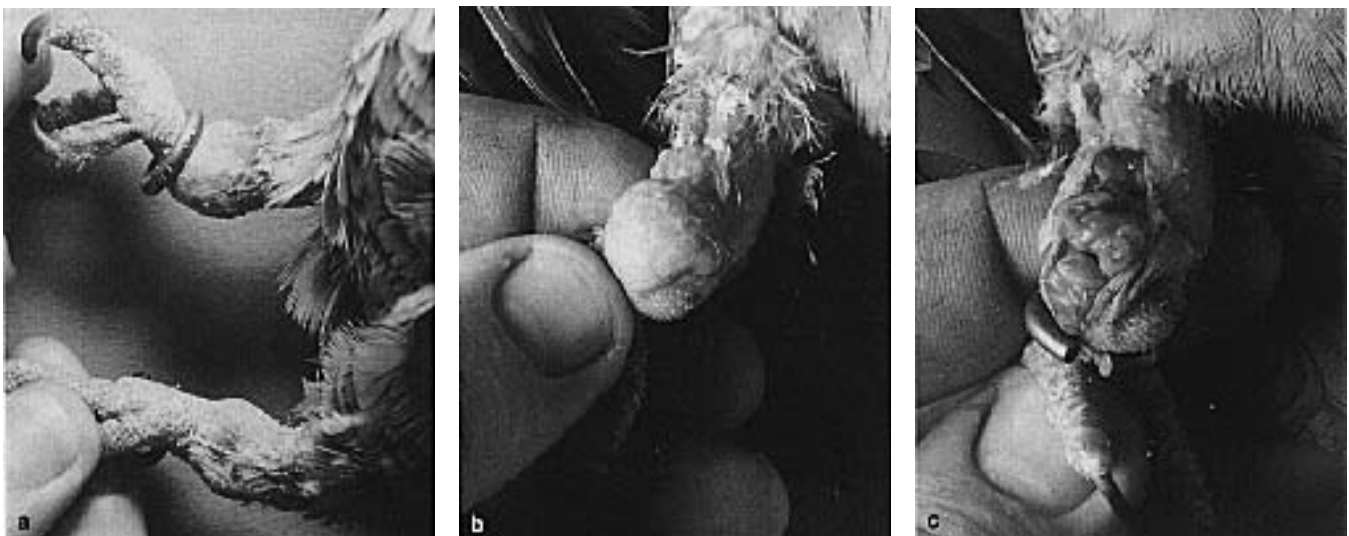


FIG 36.34 a) A Tucamon Amazon Parrot was presented with a history of bilateral, flocculent swellings of the metatarsal area. b) There were no clinical indications of discomfort or dysfunction associated with the masses. A fine-needle aspirate of the swelling revealed microfilaria. c) The masses were incised and numerous adult filariid worms (*Pelecitus* sp.) were removed.

quently diagnosed and causes prominent and disfiguring lesions (see Color 24).^{98,113} Infections are most common in budgerigars, but they may also occur in other Psittaciformes and Passeriformes. Typically, there is a proliferation of tissue on the beak. Lesions may also occur on the feet, legs and cloaca in some birds (see Color 24). Tunnels in the proliferative tissue create a characteristic honey-combed appearance. The mites can be detected by examining skin scrapings. Using an operating microscope, the adult females can be observed in the tunnels. Histologically there will be shallow burrows in which the adults will be stationed near the entrance.

Young birds are commonly affected, but adults may be infected in some situations. A genetic predisposition to develop *Knemidokoptes* infections has been suggested because only a few birds in a group may be infected. A selective immunosuppression may also be a predisposing factor, but has not been documented. In canaries, *Knemidokoptes* infections on the feet and legs may cause large proliferative masses frequently referred to as “tassel-foot” (see Color 24). *Knemidokoptes* and giardiasis are most commonly seen in inbred birds suggesting a genetic immunosuppres-

sion. Epidermoptid mites may cause hyperkeratosis, hypouricemia and feather loss. Infections are most common around the head and neck and appear to be severely pruritic.

A species of *Knemidokoptes* mite that is morphologically distinct from *K. pilae* and *K. laeris* was recovered from several groups of Red-fronted Parakeets with feather loss. The featherless skin was hyperemic and feather loss was prominent on the head and neck. The mites were identified by microscopic examination of material collected from the thickened calamus. Mites were identified in adult and immature birds but only the adults developed clinical signs.⁹⁹ Treatment consisted of two drops of a 1:20 dilution of 1% moxidectin topically on the neck.

Sternostoma tracheacolum can infect the trachea of canaries, finches (especially Lady Gouldians), parakeets and cockatiels. The larva, nymph and adult forms of the parasite can be found in the respiratory tract of affected birds, suggesting that the entire life cycle occurs in the infected host. Clinical signs include dyspnea, coughing and sneezing. Nasal discharge and open-mouthed breathing may also be




FIG 36.35 *Aralichus elongatus* mites on the ventral surface of the feathers of a White-capped Parrot. **a)** Males, females and exuvia. Note the structure of the rachs, barbules and barbs. **b)** Male (courtesy of W. T. Atyeo).

noted. Infections can be mild to severe with resulting death by asphyxiation. These small black mites can be identified by transillumination of the trachea, or the eggs can be identified in the feces or following a transtracheal wash. Young birds may be infected when being fed by infected parents. The incubation period in Gouldian Finches is three weeks but may be months in other species. Mite-free Society Finches can be used to cross-foster Gouldian Finches to produce mite-free flocks.³⁵

Numerous feather mites have been described in birds (Figures 36.35 and 36.36). Six species have been described in African Psittaciformes and three to four species have been described in Australian Psittaciformes. Fifteen species of feather mites have been described in New World Psittaciformes. Feather mites have highly specific microhabitats, infecting specific portions of the feathers. In general, feather mites are apathogenic in their host-adapted species, but can cause clinical problems in non-host adapted species, or with heavy infestations when the mites move from the feathers to the skin.

As an example of the highly specialized nature of feather mites, two species that frequently infect budgerigars were studied. *Prolichns* spp. were found to live on the exposed surfaces of the wing and tail feathers, while *Dubininia* spp. lived on the small body feathers.⁶

Myialges (*Metamicrolichus nudus*) were demonstrated in a Grey-cheeked Parakeet with sinusitis, weight loss, pruritic dermatitis and feather loss of the head. The skin was hyperkeratotic (several millimeters thick), and the parasite was demonstrated in pits within the stratum corneum and feather cavity. The females of this parasite generally attach to the exoskeleton of lice or hippoboscid flies for oviposition. The source of infection in this bird was undetermined.⁴⁹

Myialges was diagnosed by finding eggs in a skin scraping taken from an Amazon parrot with a one-week history of scratching around the eyes. The skin around the lores was dry and flaky and the head, cere and lore area appeared to be pruritic. Ivermectin was effective in controlling the infection.⁹⁴





FIG 36.36 *Rhytidelasma gaud* from an *Aratinga* sp.; **a**) Nymphs. **b**) Cast skins (exuvia). Note the barbicels of the feather (courtesy of W.T. Atyeo).

Nonhost-specific fleas are occasionally noted in companion and aviary birds. If they cause clinical problems (eg, pruritus, anemia, poor feather condition) they can be controlled with a light dusting of pyrethrin powder. The mite protectors sold in most pet supply stores have no effect on common external avian parasites and may cause liver disease. The use of these products is discouraged.

Other mites that have been associated with occasional skin or feather disease in birds include: *Dermanyssus* spp. (red mites), *Ornithonyssus* spp. (fowl mites), *K. laevis* (depluming mite), epidermoptoid mites and quill mites (*Syringophilus* spp., *Dermotoglyphus* spp., *Pterolichus* spp. and *Analges* spp.). *Der-*

manyssus feed on blood and may cause anemia, pruritus and poor growth in young birds. They infect the bird only at night and spend the daytime in crevices within the aviary. Under magnification, they can be recognized as rapidly moving dark brown spots. Free-ranging birds can serve as a source of infestation and should not be allowed to nest or roost in the aviary. *Ornithonyssus* can cause problems similar to those seen with *Dermanyssus*. This parasite completes its life cycle on the bird. Dusting with pyrethrin should be effective for controlling the mites. Quill mites may cause damage to developing feathers. The mites can be demonstrated by examining the pulp material within a developing feather.

References and Suggested Reading

- Allen JL, et al: Subcutaneous filariasis (*Pelecitus* sp.) in a yellow-collared macaw (*Ara auricollis*). Avian Dis 29:891-894, 1985.
- Anderson RC, Diaz-Ungria C: Revision preliminar de las especies de *Thelazia* Bosc (Spiruroidea: Thelaziidae), parasitas de aves. Mem Soc Cienc Nat La Salle 19:37-75, 1959.
- Angus KW: Cryptosporidiosis in man, domestic animals and birds. A review. J Royal Soc Med 76:62-70, 1983.
- Armstrong DL, et al: Cerebrospinal nematodiasis in blue and gold macaws and scarlet macaws associated with *Baylisascaris procyonis*. Proc Assoc Avian Vet, 1987, pp 489-490.
- Atkinson CT, Forrester DJ, Greiner EC: Pathology of *Haemoproteus meleagridis* (Haemosporina: Haemoproteidae) in experimentally infected domestic turkeys. J Parasitol 74:228-239, 1988.
- Atyeo WT, Gand J: Feather mites of the parakeet. J Parasit 73:203-206, 1987.
- Barlett CM, Anderson RC: *Lemdana wernaarti* n. sp. and other filarid nematodes from *Bubo virginianus* and *Asio otus* (Strigiformes) in Ontario, Canada, with a revision of *Lemdana* and a key to avian filarid genera. Canad J Zool 65:1100-1109, 1987.
- Barlett CM, Greiner EC: A revision of *Pelecitus railliet* & henry (Filarioidea, Dirofilarinae) and evidence for the "capture" by mammals of filarioids from birds. Bull Mus Natn Hist Nat, Paris 8:47-99, 1910.
- Barlett CM, Wong PL, Anderson RC: *Eulimdana lari* (Yamaguti 1935) n. comb. (Nematoda; Filarioidea) from *Phalaropus* spp. (Charadriiformes) in Canada and a review of the genus *Eulimdana* Founikoff 1934. Canad J Zool 63:666-672, 1985.
- Belton DJ, Powell IB: Cryptosporidiosis in lovebirds (*Agapornis* sp.). New Zealand Vet J 35:15, 1987.
- Bennett GF, Whiteway M, Woodworth-Lynas C: A host-parasite catalogue of the avian hematozoa. Ocas Papers Biol No. 5, 243 pp, 1982.
- Bennett GF, Peirce MA: Avian Haemoproteidae. The haemoproteids of the parrot family Psittacidae. Can J Zool 64:771-773, 1986.
- Blagburn BL, et al: *Cryptosporidium* spp. infection in the ventriculus of an Australian diamond firetail finch. Avian Dis 34:1027-1030, 1990.
- Bowie JY: *Cyathostoma cacatuae* n. sp. (Nematoda: Syngamidae) from a sulfur-crested cockatoo *Cacatua galerita* (Aves: Psittaciformes), with a key to the species of *Cyathostoma*. New Zealand J Zool 12:425-429, 1985.
- Box ED: Observations on *Giardia* of budgerigars. J Protozool 28: 491-494, 1981.
- Box ED: *Atoxoplasma* associated with an isosporan oocyst in canaries. J Protozool 17:391-396, 1970.
- Box ED: *Isospora* as an extraintestinal parasite of passerine birds. J Protozool 28:244-246, 1981.
- Box ED, Smith JH: The intermediate host spectrum in a *Sarcocystis* species of birds. J Parasit 68:668-673, 1982.
- Brooks DE, Greiner EC, Walsh MT: Conjunctivitis caused by *Thelazia* sp. in a Senegal parrot. J Am Vet Med Assoc 183:1305-1306, 1983.
- Clark WC: *Procyrnea kea* sp. nov. (Habronematidae: Spirurida; Nematoda) from the New Zealand kea (*Nestor notabilis* Gould 1865) (Aves: Psittaciformes). J Roy Soc New Zealand 8:323-328, 1978.
- Clark WC, Black H, Rutherford DM: *Microtetrameres nestoris* n. sp. (Nematoda: Spirurida), a parasite of the North Island Kaka, *Nestor meridionalis septentrionalis* (Aves: Psittaciformes). New Zealand J Zool 6:1-5, 1979.
- Clubb SL: Parasites of cage and aviary birds. Proc Amer Fed Avi Vet Sem, 1988, pp 63-68.
- Clubb SL, et al: An acute fatal illness in old world psittacine birds associated with *Sarcocystis falcatula* of opossums. Proc Assoc Avian Vet, 1986, pp 139-149.
- Clubb SL, Frenkel JK: *Sarcocystis falcatula* of opossums: Transmission by cockroaches with fatal pulmonary disease in psittacine birds. J Parasitol 78:116-124, 1992.
- Clubb SL, Cramm D: Blood parasites of psittacine birds. A survey of the prevalence of *Hemoproteus* microfilaria and *Trypanosomes*. Proc Am Assoc Zoo Vet, 1981, pp 32-37.
- Dharma DN, et al: Filariasis and microfilariasis in parrots in the eastern islands of Indonesia. Avian Dis 29:881-885, 1985.
- Dollfus RP: Miscellaneous helminthologica marocana. XLII. Cestodes d'Oiseaux et de Mammiferes. Bull Mus Natn Histoire Nat 212:659-684.
- Dorrestine GM, van der Hage MN, Zwart P: Diseases of passerines, especially canaries and finches. Proc Assoc Avian Vet, 1985, pp 53-70.
- Doster AR, Mchaffey EA, McClearn JR: *Cryptosporidium* in the cloacal coprodeum of red-lore parrots (*Amazona autumnalis*). Avian Dis 23:654-661.
- Douglass EM: Histomoniasis in zoo birds. Vet Med Sm Anim Clin July:1013-1014, 1981.
- Erlandsen SL, Bemrick WJ: SEM evidence for a new species, *Giardia psittaci*. J Parasit 73:623-629, 1987.
- Evans RH, Tangredi B: Cerebrospinal nematodiasis in free-ranging birds. J Am Vet Med Assoc 183:1089-1090, 1985.
- Farah MO: Ventriculus worm infections in the pigeon. Br Vet J 144:596-601, 1988.
- Fix AS, et al: *Plasmodium relictum* as a cause of avian malaria in wild-caught magellanic penguins (*Spheniscus magellanicus*). J Wildl Dis 24:610-619, 1988.
- Flammer K: Preliminary experiments for control of internal parasites in Australian finches. Proc West Poul Dis Conf, 1982, pp 155-157.
- Flammer K: Clinical aspects of toxoplasmosis in canaries. Proc Assoc Avian Vet, 1987, pp 33-35.
- Flatt RE, Nelson LR: *Tetrameres americana* in laboratory pigeons. Lab An Care 19:8453-856, 1969.
- Fudge AM, McEntee L: Avian giardiasis: Syndrome, diagnosis and therapy. Proc Assoc Avian Vet 1986, pp.155-164.
- Gajadhar AA: *Cryptosporidium* species in imported ostriches and considerations of possible implications for birds in Canada. Can Vet J 34:115-116, 1993.
- Garner MM, Sturtevant FC: Trichomoniasis in a blue-fronted Amazon parrot (*Amazona aestiva*). J Assoc Avian Vet 6:17-20, 1992.
- Glunder G, Hinz KH: Zum Auftreten der Leucocytozoonosis bei (Psittaciden). Kleintierpraxis 30 433-437, 1985.
- Goodwin MA: Cryptosporidiosis in birds - a review. Avian Pathol 18:365-384, 1989.
- Gothé R, Kreier JP: *Aegyptianella*, *Eperythrozoon* and *Haemobartonella*. In Kreier J (ed): Parasitic Protozoa. Academic Press, 1977, pp 254-263.
- Greiner EC: Parasite diagnosis by fecal examination. J Assoc Avian Vet 3:69-72, 1989.
- Greiner EC: Leucocytozoonosis in waterfowl and wild galliforme birds. Bull Soc Vect Ecol 16:84-93, 1991.
- Greiner EC, Walsh MT: Conjunctivitis caused by *Thelazia* sp. in a senegal parrot. J Am Vet Med Assoc 183:1305-1306, 1983.
- Greve JH, Graham DL, Nye RR: Tenosynovitis caused by *Pelecitus calamiiformis* (Nematoda: Filarioidea) in the legs of a parrot. Avian Dis 26: 431-436, 1982.
- Greve JH, Sakka AA, McGehee EH: Bilharziasis in a nanday conure. J Am Vet Med Assoc 172:1212-1214, 1978.
- Greve JH, Uphoff CS: Mange caused by *Myialges* in a grey-cheeked parakeet. J Am Vet Med Assoc 185:101-102, 1984.
- Guy JS, et al: Experimental reproduction of enteritis in bobwhite quail with *Cryptosporidium* and reovirus. Avian Dis 1987.
- Harper FDW: *Hexamita* species present in some avian species in South Wales. Vet Rec 128:130, 1991.
- Hartley WJ, Dubey JP: Fatal toxoplasmosis in some native Australian birds. J Vet Diagn Invest 3:167-169, 1991.
- Hartwich G, Tscherner V: *Ascaridia platyceri* n. sp., eine neue Spulwurmart aus Papageien. Angew Parasitol 20:63-67, 1979.
- Henderson GM, Gulland FMD, CM Hawkey: Haematological findings in budgerigars with megabacterium and trichomonas infections associated with 'going light'. Vet Rec 123:492-494, 1988.
- Hillyer EV, Quesenberry KE, Baer KE: Systemic microfilariasis in an umbrella cockatoo. Proc Assoc Avian Vet, 1988, pp 201.
- Hillyer EV, et al: An outbreak of *Sarcocystis* in a collection of psittacines. J Zoo Wildl Med 22:434-445, 1991.
- Howerth EW, et al: Fatal toxoplasmosis in a red lory (*Eos bornea*). Avian Dis 35: 642- 646, 1991.
- Hunter DB, Taylor M: Lung biopsy as a diagnostic technique in avian medicine. Proc Assoc Avian Vet, 1992, pp 207-211.
- Jacobson ER, et al: *Sarcocystis* encephalitis in a cockatiel. J Am Vet Med Assoc 185:904-906, 1984.
- Jairajpuri DS, Siddiqi AH: *Annulospira oculata* gen et sp nov (Nema-

- toda: Thelaziidae) from India. *Helminthol* 43:341-342, 1969.
61. **Kazacos KR, et al:** Fatal hepatic trematodiasis in cockatoos due to *Platynosomum proaillicens*. *Avian Dis* 24:788-793, 1980.
 62. **Kazacos KR, Fitzgerald SD, Reed WM:** *Baylisascaris procyonis* as a cause of cerebrospinal nematodiasis in ratiates. *J Zoo Wildl Med* 22:460-465, 1991.
 63. **Kazacos KR, Winterfield RW, Thacker HL:** Etiology and epidemiology of verminous encephalitis in an emu. *Avian Dis* 26:389-391, 1982.
 64. **Kock MD, Duhamel GE:** Hepatic distomatiasis in a sulphur-crested cockatoo. *Am J Vet Med Assoc* 181:1388-1389, 1982.
 65. **Latimer KS, et al:** Cryptosporidiosis in four cockatoos with psittacine beak and feather disease. *J Am Vet Med Assoc* 200:107-110, 1992.
 66. **Ley DH, et al:** *Cryptosporidium* positive rates in avian necropsy accessions determined by examination of auramine O-stained fecal smears. *Avian Dis* 32:108-113, 1988.
 67. **Ley DH:** Avian cryptosporidiosis - An emerging disease. *Proc Assoc Avian Vet*, 1987, pp 299-303.
 68. **Lindsay DS, Blagburn BL:** Cryptosporidiosis in birds. *In:* Dubey JP, et al (eds): *Cryptosporidiosis in Man and Animals*. Boca Raton, CRC Press, 1990, pp 133-148.
 69. **Lowenstine LJ, Petrak ML:** Microsporidiosis in two peach-faced lovebirds. *In:* Montali RJ (ed): *Comparative Pathology of Zoo Animals*, Smithsonian Press, pp 365-368, 1980.
 70. **Marcial MA, Madara JL:** *Cryptosporidium*: Cellular localization, structural analysis of absorptive cell-parasite membrane - membrane interactions in guinea pigs, and suggestion of protozoan transport by M cells. *Gastroenterology* 90:583-594, 1986.
 71. **McClure HE, et al:** Haematozoa in the Birds of Eastern and Southern Asia. Memorial University, St John's, Newfoundland, 296 p, 1978.
 72. **Meggitt F:** A new species of tape-worm from a parakeet, *Brotogeris tirica*. *Parasitology* 8:42-55, 1915.
 73. **Miltgen F, et al:** *Parahaemoproteus desseri* n. sp.; gametogonie et schizogonie chez l'hôte naturel: *Psittacula roseata* de Thaïlande, et sporogonie expérimentale chez *Culicoides nebeculosus*. *Annales Parasitol Hum Comp* 56: 123-130, 1981.
 74. **Miltgen F, Landau I:** *Culicoides nebeculosus*, vecteur expérimental d'un nouveau trypanosome de Psittaciforme: *Trypanosoma bakeri* n. sp. *Annales Parasitol Hum Comp* 57:423-428, 1982.
 75. **Mines JJ:** *Ascaridia sprenti*, a new species of nematode in Australian parrots. *Internat J Parasitol* 9:371-379, 1979.
 76. **Mines JJ, Green PE:** Experimental *Ascaridia columbae* infections in budgerigars. *Aust Vet J* 60:279-280, 1983.
 77. **Minsky L, Petrak ML:** Diseases of the digestive system: *In* Petrak ML (ed): *Diseases of Cage Aviary Birds* 2nd ed. Philadelphia, Lea & Febiger, 1982, pp 432-443.
 78. **Morata K:** Avian haematozoa and microfilaria infections in imported psittacine birds. *J Japan Vet Med Assoc* 43:271-274, 1990.
 79. **Murtaug RJ, Jacobs RM:** Trichomoniasis of the crop in a cockatiel. *J Am Vet Med Assoc* 185:441-442, 1984.
 80. **Myers RK, Monroe WE, Greve JH:** Cerebrospinal nematodiasis in a cockatiel. *J Am Vet Med Assoc* 183:1089-1090, 1983.
 81. **Page CD, et al:** Antemortem diagnosis and treatment of sarcocystosis in two species of psittacines 23:77-78, 1992.
 82. **Page DC, Schmidt RE, Hubbard GB:** *Sarcocystis* myocarditis in a red lory. *J Zoo Wildl Med* 20:461-464, 1989.
 83. **Panigraphy B, et al:** Diseases of pigeons and doves in Texas: Clinical findings and recommendations for control. *J Am Vet Med Assoc* 181:384-386, 1982.
 84. **Panigraphy B, et al:** Zoonotic diseases in psittacine birds: apparent increased occurrence of chlamydiosis (psittacosis), salmonellosis and giardiasis. *J Am Vet Med Assoc* 175:359-361, 1979.
 85. **Parrington CJ, et al:** Atoxoplasmosis in Bali mynahs. *J Zoo Wildl Med* 20:328-335, 1989.
 86. **Peirce MA:** Blood parasites found in imported birds at postmortem examination. *Vet Rec* 84:113-116, 1969.
 87. **Peirce MA, Bevan BJ:** *Ascaridia galli* (Schränk 1788) in psittacine birds. *Vet Rec* 92:261, 1973.
 88. **Peirce MA, Bevan BJ:** Blood parasites of imported psittacine birds. *Vet Rec* 100: 282-283, 1977.
 89. **Poonacha KB, Williams PD, Stamper RD:** Encephalitozoonosis in a parrot. *J Am Vet Med Assoc* 186:700-701, 1985.
 90. **Price RD, Clayton DH:** A review of the genus *Psittaconirmus* (Mallophaga: Philopteridae) from South Pacific parrots (Psittaciformes). *Internat J Entomol* 25: 56-70, 1983.
 91. **Price RD, Emerson KC:** The *Neopsittaconirmus* (Mallophaga: Philopteridae) from *Cacatua* (Aves: Psittaciformes). *Pacific Insects* 18:33-36, 1978.
 92. **Quesenberry KE, et al:** Hepatic trematodiasis in five cockatoos. *J Am Vet Med Assoc* 189:1103-1105, 1986.
 93. **Randall CJ, et al:** Microsporidian infection in lovebirds (*Agapornis* spp.). *Avian Pathol* 15:223-231, 1986.
 94. **Remington KH:** *Myialges nudus* in a lilac-crowned Amazon. *Proc Assoc Avian Vet*, 1990, pp 312-313.
 95. **Roskopf WJ, Woerpel RW:** Pet avian conditions and syndromes. *Proc Assoc Avian Vet*, 1989, pp 394-424.
 96. **Roskopf WJ, Woerpel RW, Roskopf GA:** Blood parasites in caged birds. *Vet Med Sm Anim Clin* 1763-1765, 1981.
 97. **Scholtens RG, New JC, Johnson S:** The nature and treatment of giardiasis in parakeets. *J Am Vet Med Assoc* 180: 170-173, 1982.
 98. **Shane SM, Stewart TB, Confer AW:** *Knemidokoptes pilae* infestation in the palm cockatoo. *Avian/Exotic Pract* 2:21-25, 1985.
 99. **Shoshana R:** *Knemidokoptes*: Mites on feathers of the red-fronted parakeet. *Proc Europ Assoc Avian Vet*, 1993, pp 329-331.
 100. **Smith JH, Neill PJG, Box ED:** Pathogenesis of *Sarcocystis falcatula* (Apicomplexa: Sarcocystidae) in the budgerigar (*Melopsittacus undulatus*) III. Pathologic and quantitative parasitologic analysis of extrapulmonary disease. *J Parasitol* 75:270-287, 1989.
 101. **Smith JH, et al:** Pathology of experimental *Sarcocystis falcatula* infections of canaries and pigeons. *J Parasitol* 76:59-68, 1990.
 102. **Sood ML, Kalia R:** Records of two nematode parasites uncommon in birds. *Acta Parasit Polonica* 23:361-365, 1975.
 103. **Spillmann SK, Ehrsam HR, Ossent P:** *Leucocytozoon*-Infektionen bei Sittichen. *Schweiz Arch Tierheilk* 129:215-219, 1987.
 104. **Stabler RM:** *Trichomonas gallinae*: A review. *Exp Parasitol* 3:368-402, 1954.
 105. **Sundermann CA, Lindsay DS, Blagburn BL:** Evaluation of disinfectants for ability to kill avian *Cryptosporidium* oocysts. *Comp Anim Prac* 1:36-39, 1987.
 106. **Theodoropoulos G, Greve JH:** Observations on the morphology of the eye-worm *Ceratomyxa inglesi* (Nematoda: Thelaziidae) from a moluccan cockatoo. *Proc Helm Soc Wash* 52: 132-133, 1985.
 107. **Tsai SS, et al:** Cryptosporidiosis in domestic birds. *Chinese J Micro Immunol* 16:307-313, 1983.
 108. **Varghese T:** *Eimeria haematodi* sp. n. (Protozoa: Eimeriidae) from the rainbow lorikeet, *Trichoglossus haematodus*, in Papua New Guinea. *J Parasitol* 63:210-211, 1977.
 109. **Wakelin D:** Nematodes of the genus *Capillaria* Zeder 1800 from the collection of the London School of Hygiene and Tropical Medicine. *J Helminthol* 41:257-268, 1967.
 110. **Webster WA, Speckmann G:** The description of a gubernaculum in *Ascarops strongylina* (Rudolphi 1819) (Spiruroidea) and a note on the recovery of this nematode from a bird. *Canad J Zool* 55:310-313, 1977.
 111. **Wilso RB, New JC, Scholtens RG:** Granulomatous encephalitis caused by schistosomiasis in swans. *J Am Vet Med Assoc* 181:1386-1388, 1982.
 112. **Wojcinski ZW, et al:** An outbreak of schistosomiasis in Atlantic brant geese. *J Wild Dis* 23:248-255, 1987.
 113. **Yunker CE, Ishak KG:** Histopathological observations on the sequence of infection of knemidokoptic mange of budgerigars (*Melopsittacus undulatus*). *J Parasitol* 43:664-669, 1957.