

CHAPTER

37

TOXINS

Genevieve Dumonceaux
Greg J. Harrison

Birds are curious pets and frequently investigate unusual textures, containers and locations throughout the home. Many of the items that birds may encounter during these quests can be dangerous. Contact with or consumption of certain plants, cleaners, pesticides and household disinfectants may cause acute or chronic intoxication. Even some types of foods provided to birds can be toxic.

Most compounds considered toxic to mammals should also be considered toxic to birds. Table 37.1 offers a guide for treatment of intoxication from some common household products. Based on their size and physiology, birds are more prone than mammals to intoxication by some compounds, such as volatile chemicals and fumes. Psittaciformes have a propensity to chew on almost anything. All avian clients should “bird-proof” their homes to provide a safe and enjoyable environment for their companion birds.

Birds should be supervised at all times when out of their enclosures. It has been suggested that the consumption of foreign bodies (eg, metal, wood, jewelry), over-consumption of grit and coprophagy may all be mediated by malnutrition (Gerlach H, unpublished). Therefore, birds on a formulated diet would be expected to chew less on plants, perches and toys than birds on a seed-based diet.

TABLE 37.1 Normal Household Compounds That May be Toxic to Birds

Agent	Toxic Components	Clinical Effects	Therapy
Bleaches, pool chemicals	Chlorine	Photophobia, epiphora, coughing, sneezing, hyperventilation, GI irritation or ulceration	Dilution with water or milk orally. Irrigate skin with cool water. GI protectant, demulcent
Cleaning agents, accumulated excrement	Ammonia	Respiratory tract irritation, immune suppression	Fresh air, antibiotics, supportive care
Combustion exhaust (autos, furnaces)	Carbon monoxide	Somnolence, depression, cyanosis, death	Fresh air, oxygen, warmth, support
Denture cleaners	Sodium perborate	Direct irritation, salivation, lacrimation, vomiting, sometimes CNS depression	Irrigate with water, GI protectant, demulcent
Deodorants	Aluminum chloride, aluminum chlorhydrate	Oral irritation and necrosis, hemorrhagic gastroenteritis, incoordination and nephrosis	Careful lavage of crop and proventriculus
Detergents (anionic)	Sulfonated or phosphorylated forms, alkaline product	Dermal irritation, vomiting, diarrhea, GI distension, usually not fatal	Lavage with water
Detergents (cationic)	Quaternary ammonium with alkyl or anyl substituent groups	Vomiting, depression, collapse, coma, may cause corrosive esophageal damage	Oral milk or activated charcoal. Soap for surface areas. Treat seizures and shock as needed
Drain cleaners	Sodium hydroxide, sodium hypochlorite	Caustic to skin and mucous membranes, irritation, inflammation, edema, necrosis, burns in mouth, tongue, pharynx	Flush affected areas with water or milk. Do not use emetics or lavage. Treat for shock and pain
Fireworks	Nitrates, chlorates, mercury, antimony, copper, strontium, barium, phosphorus	Abdominal pain, vomiting, bloody feces, rapid shallow respiration, chlorates may cause methemoglobinemia	Crop or gastric lavage. Use methylene blue or ascorbic acid for methemoglobinemia. Treat for specific metal(s) ingested
Furniture polish	Petroleum, hydrocarbons, mineral spirits	Early CNS depression, disorientation, necrosis, mucosal irritation, aspiration or hydrocarbon pneumonia, hepatorenal damage	Prevent aspiration pneumonia. Avoid gastric lavage or proceed with caution. Monitor and treat for pneumonia
Gasoline, crude oil	Petroleum and petroleum distillates	GI irritation, skin and feather damage, aspiration pneumonia	Wash feathers and skin with mild soap and water. Vegetable or mineral oil gavage. Antibiotics and supportive care
Matches	Potassium chloride	Gastroenteritis, vomiting, chlorates may induce methemoglobinemia with cyanosis and hemolysis	Treat symptomatically. Use methylene blue or ascorbic acid for methemoglobinemia
Paint/varnish removers	Benzene, methanol, toluene, acetone	Dermal irritation, depression, narcosis, pneumonia, hepatorenal damage	See "furniture polish." Rinse contact areas thoroughly with warm water
Pencils	Graphite	GI irritation	Demulcent
Perfumes	Volatile oils	Local irritation of skin and mucous membranes, pneumonitis, hepatorenal damage with albuminuria, hematuria, glycosuria, excitement, ataxia, coma	If ingested, gastric or crop lavage with weak bicarbonate solution. Prevent aspiration. Demulcents. Provide plenty of ventilation
Pine oil disinfectants	Pine oil 5-10%, phenols 2-6%	Gastritis, vomiting, diarrhea, followed by CNS depression, occasional mild seizures, phenols may induce nephrosis	If ingested, gastric lavage with caution to prevent aspiration. Mineral oil. Monitor pulmonary and renal function. Provide fresh air if strong fumes are present
Overheated non-stick cookware, drip pans, heat lamps, irons, ironing board covers	Polytetrafluoroethylene	Sudden death, dyspnea, depression, pulmonary hemorrhage	Fresh air or oxygen, fluids, steroids for pulmonary edema, antibiotics, supportive care
Poor grade peanuts, peanut waste, moldy grains, corn and corn screenings, moldy cheeses, meats	Mycotoxins: aflatoxin, ochratoxin, trichothecenes	Gastrointestinal irritation, dermal irritation, oral necrosis, secondary infections due to immunosuppression	Clean feed, antibiotics for secondary infections. Treatment as indicated for clinical syndromes

table continued on next page

Agent	Toxic Components	Clinical Effects	Therapy
Rodenticides	Anticoagulants	Weakness, dyspnea, hemorrhage, petechiation, anemia	Vitamin K ₁ (2.5-5 mg/kg) IM or PO q 24 hr. Minimize stress. Warfarin, treat for 10-14 days. Chlorophacinone, treat for 21-28 days. Brodifacoum, treat for 28-30 days
Rodenticides	Cholecalciferol	Causes hypercalcemia and renal failure, vomiting, diarrhea, depression, anorexia, polyuria, polydipsia	Activated charcoal, fluid therapy. If hypercalcemic, saline diuresis, prednisolone PO 2 mg/kg q 12 hr, furosemide 2-5 mg/kg q 8-12 hr, salmon calcitonin SC 4-6 IU/kg q 2-3 hr until calcium stable (mammalian protocol)
Rubbing alcohol	Ethyl alcohol	Impaired motor coordination, cutaneous hyperemia, vomiting, progress to peripheral vascular collapse, hypothermia	Gastric or crop lavage. Monitor temperature, cardiac and pulmonary function
Shampoo	Laurel sulfates and triethanolamine dodecyl sulfate	Ocular irritation, stimulation of mucous production, ingestion causes diarrhea	Activated charcoal or kaolin orally
Salt, crackers, chips, prepared foods, salt water, sea sand (as grit)	Sodium chloride	Gastrointestinal irritation, dehydration, depression, weakness, PU/PD, death	Rehydration, offer small amounts of water frequently. SC, IV or IO fluids, supportive care
Styptic pencil	Potassium aluminum sulfate	Corrosive due to release of sulfuric acid during hydrolysis of the salt, oral necrosis from chewing on pencils	Oral neutralizer such as magnesium oxide or hydroxide. Do not give bicarbonate orally for acid poisonings

Many of the therapeutic recommendations for the above products have been taken from small animal sources.^{8,8a,36a,46a}

TABLE 37.2 Some Commonly Encountered Toxins and their Potential Effects in Birds¹⁹

Alcohol	Depression, regurgitation	Levamisole	Depression, vomiting, ataxia, mydriasis, paralysis, death (hepatotoxicity)
Aminoglycosides	Renal tubular necrosis	Lincomycin	Death
Arsenic	Pruritus, polyuria, dyspnea, death	Medroxyprogesterone	Lethargy, obesity, polydipsia, fatty liver
Atropine	Gastrointestinal stasis	Mercury	Depression, hematuria, death
Brodifacoum	Death	Metronidazole	Death in finches
Cephaloridine	Blindness	Nicosamide	Death
Chloramphenicol	Death	Nicotine	Depression, dyspnea, coma, death
Chlorine	Epiphora, upper respiratory signs, tachypnea	Nitrates	Anorexia, vomiting, diarrhea, ataxia, convulsions, death
Chocolate	Vomiting, diarrhea, death	Nitrofurazone	Ataxia, convulsions, death
Cigarette smoke	Dermatitis, sinusitis, pneumonitis	Nitrothiazole	Death
Copper	Anemia, weakness, death	Polymyxin B	Lethargy, ataxia, vomiting, death
Coumarin	Fatal hemorrhage	Polytetrafluoroethylene gas	Dyspnea, seizures, death
Cythioate	Death	Praziquantel	Depression, death
Diazinon	Death	Procaine penicillin	Paralysis, death
Dihydrostreptomycin	Paralysis, death	Rotenone	Vomiting, ataxia, convulsions, death
Dimetridazole	Incoordination, ataxia, seizures, death	Selenium sulfide	Death
Fenbendazole	Depression, ataxia, mydriasis	Sodium chloride	Depression, PU/PD, ataxia, convulsions, death
Formaldehyde	Epiphora, upper respiratory signs, death	Ticarcillin	Hepatotoxicity
Gentamicin	Apnea, renal tubular necrosis, death	Vitamin D ₃	Calcification of kidneys and other organs
Ivermectin (propylene glycol formulation)	Weakness, death	Zinc	Depression, vomiting, ataxia, death
Lead arsenate	Depression, CNS signs, death		




FIG 37.1 Psittacine birds may be exposed to numerous toxins because of their chewing behaviors. In this case, a conure was presented with lead poisoning secondary to the consumption of lead-containing solder used to hold his feeding dish. The case was further complicated by gastrointestinal impaction secondary to the ingestion of pieces of the plastic dish and malnutrition caused by a diet of wild bird seeds. Clinicians should carefully evaluate the environment in birds with clinical signs consistent with toxicity.

Birds are generally more susceptible to inhaled toxins than mammals because of their rapid metabolic rate, small size, highly efficient respiratory system and low body fat content. In comparison, many compounds that cause intoxication following ingestion by mammals are relatively nontoxic in companion birds; however, birds should be restricted from access to compounds known to be toxic in mammals (Figure 37.1).

Products that produce fumes, fogs or mists are not recommended for use in areas where birds are present. Good ventilation should be maintained to prevent the accumulation of harmful gases and fumes. Some toxins may be absorbed directly through the skin causing systemic intoxication, while others cause localized reactions (eg, nicotine dermatitis). Systemic intoxication could occur from birds perching on wood or branches treated with preservatives or pesticides.

A bird's response to a toxin may vary depending on the age, size, health status and plane of nutrition of the patient, as well as on the route, duration and quantity of toxin exposure. A malnourished bird is more likely to develop clinical problems from a toxin exposure than is a bird on an adequate diet. A bird suffering from chronic malnutrition is more likely to develop pansystemic diseases following exposure to toxic agents. Table 37.2 lists some compounds that have been associated with toxicity in birds and their principal clinical changes.

Free-ranging birds, particularly Anseriformes, are commonly poisoned through chronic exposure to a contaminated, abused environment. Toxin-contaminated water, air and food supplies can affect birds through direct contact or through poisoning of components in the food chain. Often the intoxication is subtle, and poisons accumulate over time (eg, lead in waterfowl, organochlorines in birds of prey).

Birds of prey and fish-eating birds are particularly susceptible to contaminants in the food chain because of biologic magnification. It is of interest that the health of free-ranging birds is frequently ignored as a sensitive indicator of human-induced damage to our environment.

In addition to human-related toxins, food and water supplies encountered by free-ranging birds may also be contaminated by biologic organisms that produce their own toxins, including molds (mycotoxins), bacteria (endotoxins) and certain blue-green algae (hepatotoxins).

When submitting samples for toxicologic analysis, it is best to call the laboratory for information on proper sample preparation and shipment. Most laboratories request frozen samples (except whole blood), preferably individually wrapped to prevent cross-contamination. Samples submitted for heavy metal analysis should not be wrapped in foils or contact any metal during shipment. Complete request forms, including the specific analyses to be run and the species involved, improve the speed and accuracy of the results.

Further information on products and chemicals as well as assistance with poisonings is available from the National Animal Poison Control Center, University of Illinois, College of Veterinary Medicine, Urbana, IL 61801, 1-800-548-2423 (credit cards only, \$30 per case) or 1-900-680-0000 (\$20 for the first 5 minutes, plus \$2.95 for each additional minute [\$20 minimum]). This center's experience is limited when dealing with companion birds and they often refer calls to experienced practitioners.

A useful conversion in toxicology analysis is 1 ppm = 100 µg/dl.

Ingested Toxins

Lead (Pb)

Lead intoxication is one of the most commonly reported and clinically recognized poisonings of companion and free-ranging birds. Lead is inconspicuously included in numerous products found around the home and the precise cause of lead intoxication is frequently undetermined. Table 37.3 offers some examples of possible household sources of lead. The common lead weights used to balance wheels may be an underestimated source of contamination within a bird's environment. Once ingested, the lead is degraded by acids in the stomach and absorbed into the bloodstream. Raptors can be exposed to lead by ingesting carcasses containing lead shot. Unless paints state that they are "lead free" they may still have toxic levels of lead in the drying agent rather than in the base. Lead exposure may also occur through the inhalation of fumes from lead-containing gasoline (Figure 37.2).

Lead deposited in muscle tissue of birds is generally considered to pose minimal health risks; however, lead shot implanted subcutaneously and intramuscularly in pigeons resulted in decreased levels of delta-aminolevulinic acid dehydratase (ALAD) enzyme activity, indicating the absorption of lead into the bloodstream.⁵¹

TABLE 37.3 Potential Sources of Lead

▪ Weights (curtains, penguin bird toys, fishing and diving, sailing and boating accessories, wheel balances)	▪ Base of light bulbs
▪ Bells with lead clappers	▪ Linoleum
▪ Batteries	▪ Contaminated bone meal and dolomite products
▪ Solder	▪ Leaded gasoline fumes
▪ Lead pellets from shotgun shells	▪ Glazed ceramics (especially imported products)
▪ Air rifle pellets	▪ Costume jewelry
▪ Lead-based paints (varnishes, lacquers)	▪ Contaminated cuttlefish bone
▪ Lead-free paints with leaded drying agents	▪ Plaster
▪ Hardware cloth	▪ Stained glass (decorative glass) – lead seam
▪ Galvanized wire (lead and zinc)	▪ Seeds for planting (coated with lead arsenate)
▪ Champagne and wine bottle foils (some)	▪ Some lubricants (lead naphthalate)

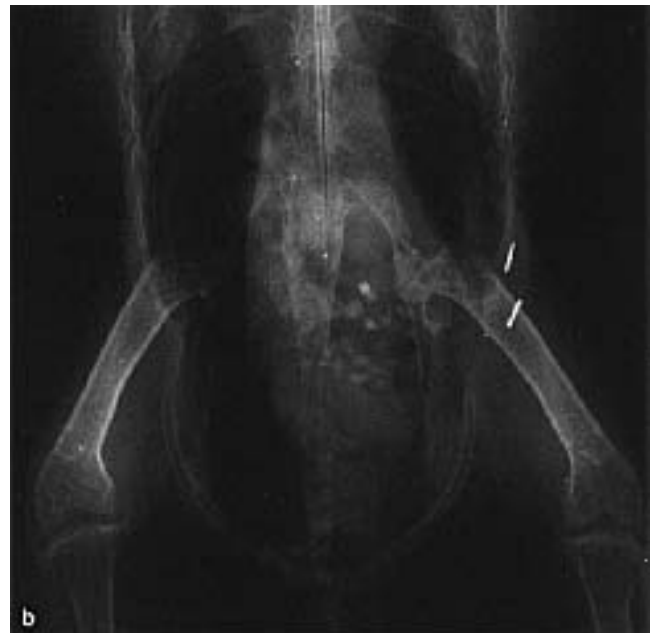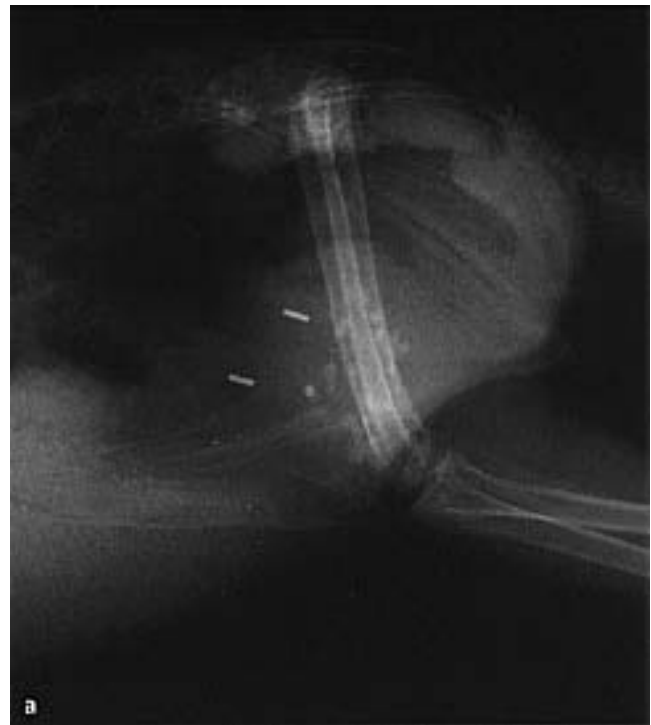


FIG 37.2 A mature cockatoo was presented with a history of an acute onset of depression, regurgitation and diarrhea. **a)** It is a common but inappropriate practice to obtain only a lateral radiograph when attempting to detect heavy metals in the gastrointestinal tract. **b)** In this case, two metal-density objects that appeared to be in the proventriculus and ventriculus were found to be hemostatic clips that had been used in a previous laparotomy incision.

Lead poisoning and death occurred in an African Grey Parrot that was sprayed with an automobile lubricant^a to prevent feather picking. The product contained 4.5% lead naphthenate and had previously been used to treat a lovebird that died with a similar clinical progression. Radiographic and clinical pathology data were unremarkable. The bird's only clinical signs were diarrhea, anorexia and depression.⁶⁵ Blood lead levels in the bird were 3.9 $\mu\text{mol/l}$ (78 $\mu\text{g/dl}$) suggesting lead intoxication. Neither the product label nor information sheet divulged that it contained such a high level of lead.

A simple lead testing kit^b is available for the detection of lead in environmental samples. A swab supplied with the kit is moistened with a supplied reagent and rubbed against an item to be tested (eg, wire, paint). The tip of the swab turns red if lead is present in the sample. This rapid, in-home test is less reliable than tests performed by commercial laboratories.

Clinical Signs

Clinically, lead toxicosis may occur as an acute or a chronic problem. Chronic intoxications are most common in Anseriformes and other free-ranging birds. The chronicity of these problems probably occurs because the animals are not evaluated until critically ill from prolonged intoxication. The most commonly reported effect in free-ranging birds is a decrease in population densities. Because companion birds are carefully observed on a daily basis, the non-specific signs of acute lead toxicosis are frequently recognized and birds are presented for medical evaluation.

The presence and severity of clinical signs depends on the amount of lead ingested, the surface area of the particles and the length of time the lead is in the gastrointestinal tract.^{19,36} The type and amount of abrasive material in the ventriculus alters the speed of lead digestion and may affect the type of clinical presentation.³⁶

Once in the bloodstream, lead causes pansystemic damage, particularly to the gastrointestinal, nervous, renal and hematopoietic systems. Clinical signs of lead intoxication in psittacine birds may include lethargy, depression, anorexia, weakness (wing droop, leg paresis), regurgitation, polyuria, diarrhea, emaciation, ataxia, head tilt, blindness, circling, paresis, paralysis, head tremors, convulsions and death.^{19,35,36} Some birds may die with no clinical signs and in others, the only noted abnormalities may be weakness and chronic weight loss.⁶⁵ Hemoglobinuria

has been reported as a clinical sign of lead poisoning in Amazon and African Grey Parrots, but it may not occur in all cases.⁷² This finding is thought to be secondary to intravascular hemolysis and is frequently misinterpreted as bloody diarrhea.³⁶ Lead poisoning in waterfowl, cranes and pigeons may cause ileus of the crop, esophagus, proventriculus and ventriculus.⁶ In waterfowl and poultry, lead poisoning can cause clinical signs similar to those that occur with botulism. Response to chelation therapy (lead or zinc) or antitoxin (botulism) is suggestive of a diagnosis (see Chapters 28, 33, 46).

Pathology

In some cases, hematologic parameters may provide an indication of lead intoxication. A hypochromic, regenerative anemia occurs in some affected birds.³⁶ Basophilic stippling and cytoplasmic vacuolization of red blood cells reported in mammalian lead poisoning cases are not recognized in avian patients.

Elevations of LDH, AST and CPK have been reported. Increased LDH and AST are primarily related to liver damage in birds. High CPK activities may be a result of lead-induced neuronal damage.¹⁴

The functional capacity of the renal system should be carefully evaluated in birds suspected of having lead poisoning. Most commonly used chelating agents have potentially nephrotoxic side effects, and therapy for heavy metal intoxication should be instituted with caution in birds with impaired renal function. There are no reports detailing serious nephrotoxic side effects from the use of chelation therapy in companion birds; however, swans that did not recover from lead poisoning with chelation therapy had markedly elevated uric acid levels, visceral gout and renal nephrosis.⁶

Gross necropsy findings in lead-poisoned swans include weight loss and green liver tissue. Histologic lesions are most severe in birds that survive for several weeks. In these birds, necrohemorrhagic enteritis secondary to *Clostridium perfringens* is common. Other findings include fibrinoid vascular necrosis, renal nephrosis and multifocal myocardial degeneration.⁶

Radiography

The identification of metallic densities in the gastrointestinal tract of birds with clinical signs of heavy metal intoxication is suggestive. However, the absence of metal densities in the presence of clinical signs does not rule out heavy metal intoxication (Fig-

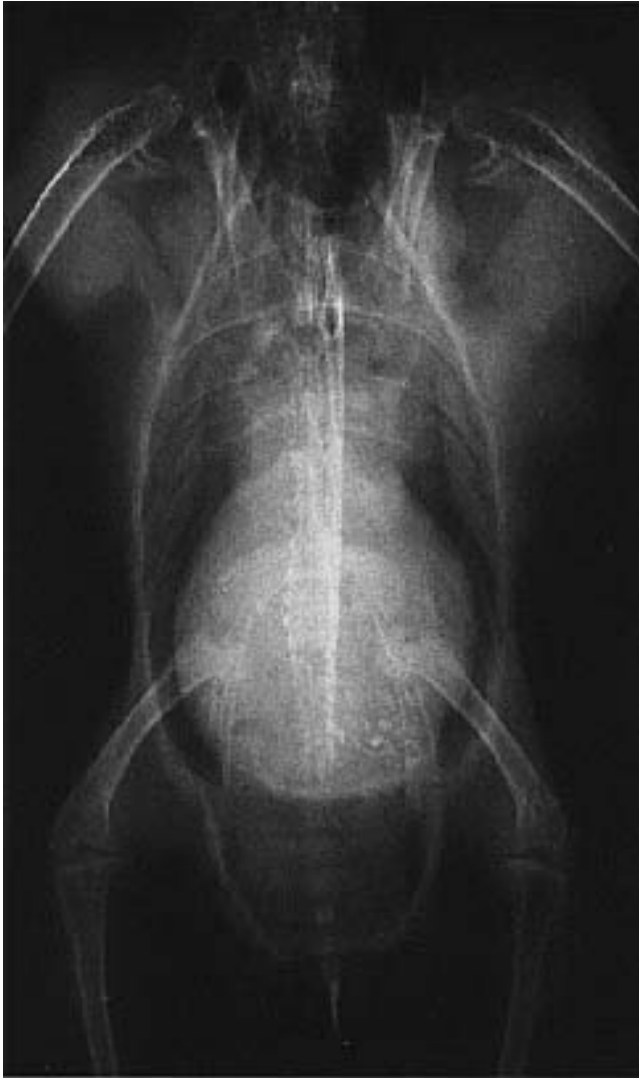

FIG 37.3 A two-year-old female Rose-breasted Cockatoo was presented with dyspnea and weight loss (257 g). Abnormal clinical pathology findings included WBC=48,000 (toxic heterophils), LDH=2791, AST=1562, bile acids=291. The bird was negative for chlamydia by ELISA antigen testing of the excrement. Zinc levels were 370 µg/dl. Radiographs indicated severe hepatomegaly and an auxiliary mass that was determined by cytology to be a lipoma. One week after initiating therapy with CaEDTA, clinicopathologic findings included AST=901, LDH=1500 and bile acids=613.

ure 37.3). In one study involving swans, 25% of lead poisoned birds did not have lead pellets that could be identified by radiographs.^{6,19} Some intoxications can occur from absorption of lead that is in a nonradiodense form (eg, paint chips or gas fumes), or a bird can develop clinical signs following the mobilization of lead stored in the bones months after an initial ingestion has occurred.

Metal particles usually are visualized in the ventriculus but may be seen anywhere along the gastrointestinal tract. In chronic cases involving free-ranging birds, eroded pellets have been radiographically documented at necropsy.¹⁹ In some cases, the source of lead may be eliminated from the gastrointestinal tract before clinical signs are recognized.

Toxicologic Analysis

Several blood tests are available to confirm lead intoxication. They require a small volume of blood, but results require from four days to several weeks. Whole, unclotted blood is the sample of choice for determining lead concentrations because 90% of circulating lead is in red blood cells. Lithium heparin is a suitable anticoagulant. EDTA should not be used because this anticoagulant may interfere with testing.³¹ Diagnostic blood levels may vary widely between species.

Whole blood lead levels greater than 20 µg/dl (0.2 ppm; 1.25 µmol/dl) are suggestive, and levels greater than 40 to 60 µg/dl (0.4 to 0.6 ppm; 2.5 µmol/dl) are diagnostic of lead intoxication in psittacine birds when accompanied by appropriate clinical signs (Table 37.4).^{19,30} Some birds may have clinical signs and respond to therapy with levels as low as 10 µg/dl. Blood from a normal bird of the same species can be submitted along with that of the ill patient to allow more accurate interpretations of the laboratory results. Higher levels of blood lead have been reported in many avian species with no clinical signs of intoxication.³⁰

In cockatiels experimentally exposed to lead, peak blood concentrations ranged from 44 to 129 µg/dl.³⁶ In a study involving zinc toxicosis, the cockatiels in the experimental group had a mean blood lead level of 5 µg/dl.²¹ In adult Cuban Whistling Tree Ducks, the blood lead level of one affected bird was 163 µg/dl; compared with the normal value of its mate of 32 µg/dl. An affected Eastern Turkey Vulture in that same report had a blood lead level of 320 µg/dl.²² In Mallards and Bald Eagles, values have been reported as high as 500 µg/dl.³⁶ A Blue and Gold Macaw with

TABLE 37.4 Suggested Normal Blood Lead Levels

Swan	6 µg/dl
Mallard	5 – 39 µg/dl
Canada Goose	10 – 37 µg/dl
Pigeon	17 – 81 µg/dl
Cockatiel	5 µg/dl
Most Psittaciformes	<20 µg/dl

lead and zinc poisoning (exposure to galvanized wire) had a reported blood lead level of 50 µg/dl and a blood zinc level of 1500 µg/dl.⁴⁰

With the wide range of lead values reported in blood, this criterion alone may not be sufficient to diagnose clinical lead poisoning.³¹ Other reports disagree.³⁶ With a strong suspicion of lead intoxication, therapy should be initiated while awaiting laboratory results. A rapid response to therapy lends evidence to a diagnosis of lead (or other similar heavy metal) poisoning.³⁶

The inhibition ALAD activity has been used as a reliable and sensitive indicator of exposure to lead in ducks.^{6,19,36} It also has been recommended as a diagnostic tool in other avian species. In cockatiels, ALAD activities less than 86 units were considered indicative of lead poisoning.³⁶ In two studies in ducks, lead concentrations of 0.5 ppm in the brain and 200 ppm in the blood were found to correlate with a 75% decrease in ALAD activity in the blood.⁷

Detecting ALAD activity may be of value only in birds with low levels of lead exposure because enzyme activities failed to decrease in humans and pigeons with high exposures to lead.³¹ In swans, ALAD activities could not be used as a prognostic indicator for recovery. Additionally, in swans, as the blood levels increased, the ALAD activity was also found to increase rather than decrease.⁶ ALAD activity returned to normal in many birds that were treated but subsequently died.⁶

Lead interferes with ALAD activity, which reduces heme synthase activity and causes an increase in protoporphyrin IX concentrations in the blood. Free erythrocytic protoporphyrin (FEPP) and zinc protoporphyrin (ZPP) levels are considered accurate methods of detecting lead intoxication in birds.³¹ FEPP levels were found to be suggestive of acute toxicity, while ZPP levels were of more value in documenting chronic lead poisoning. Total protoporphyrin levels were not considered an effective prognostic indicator of recovery.

Blood protoporphyrin levels that exceed 40 ppm are common following lead ingestion. CNS signs occur with levels of 500 ppm. Protophyrin levels drop rapidly following chelation therapy. Instrumentation used to measure protoporphyrin levels in humans must be altered by removing the filters to compensate for the low levels of zinc protoporphyrin that occur in avian erythrocytes.^{31,55} Diagnostic results may be obtained with one or two microhematocrit tubes of whole blood.³⁶

Treatment

Supportive care for heavy metal poisoning may include chelation therapy (both oral and IM), intravenous lactated Ringer's, 5% dextrose solution, multi-complex B vitamins, iron dextran, antibiotics, assisted alimentation and prophylactic treatment for aspergillosis (waterfowl).⁶

The prognosis for lead intoxication is guarded if chronic exposure has occurred or if the bird has severe CNS signs. In other cases, the response to therapy is dramatic, with most patients responding to chelation therapy within six hours of administration. Many hematuric birds can die in this same time period. Gastrointestinal stasis and impaction of the proventriculus is a complicating factor in waterfowl.⁶

Chelation therapy is designed to remove lead circulating in the bloodstream. Calcium disodium ethylene diamine tetracetate (CaEDTA) or calcium disodium versenate are commonly used chelation agents. The calcium form of EDTA should be used to reduce the chances of drug-induced hypocalcemia.²⁷

The recommended dosage of CaEDTA is 10-40 mg/kg twice daily intramuscularly. CaEDTA is poorly absorbed from the gastrointestinal tract and must be used parenterally to remove circulating lead in critically ill patients.³⁶ Chelation therapy should be used for the least amount of time that is necessary to resolve the intoxication. In general, therapy should not persist for over ten days without a break in drug administration; however, some clinicians have used CaEDTA until there is no radiographic evidence of lead in the gastrointestinal tract (up to 30 days) with no clinically apparent side effects.^{28,36,40} CaEDTA may be administered orally at twice the injectable dose two to three times daily in asymptomatic birds to prevent lead from being absorbed.⁷² CaEDTA must be used carefully as it may cause gastrointestinal and renal toxicosis.^{25,36} If evidence of chelation toxicosis is seen (eg, polydipsia, polyuria, proteinuria, hematuria), CaEDTA should be discontinued for a period of five to seven days. Therapy can then resume if the patient is stable.

D-penicillamine (PA) is an effective lead chelator that can be used orally (55 mg/kg twice daily). It has been suggested that PA may increase the gastrointestinal absorption of lead;³⁰ however, more recent reports suggest that PA is a superior chelating agent to CaEDTA and does not increase absorption.³⁵ Combining CaEDTA and PA for several days until a bird is asymptomatic followed by the use of PA for three to

TABLE 37.5 Chelating Agents for Heavy Metal Toxicities

CaEDTA	Beryllium, copper, cerium, iron, zinc, lead
BAL (dimercaprol)	Arsenic, gold, mercury, copper, iron, nickel, thorium, zinc, lead
D-Penicillamine	Copper, mercury, lead, zinc

six weeks may prove to be the best therapeutic regime for lead poisoning. Birds should be monitored for clinical signs of copper depletion including lethargy, anemia and weight loss.

Dimercaprol (British Anti-Lewisite - BAL) is the best agent for removing lead from the CNS; however, this agent is rarely used because of its low therapeutic index and the positive response of most birds to PA or CaEDTA. The recommended treatment regime is 2.5 mg/kg IM every four hours for two days, then twice daily for up to ten days or until clinical signs resolve (Table 37.5).²⁷

Lead-induced seizures can be controlled with diazepam at 0.5-1 mg/kg intramuscularly two to three times daily as needed.³⁶ The primary therapy for any heavy metal intoxication is to remove the source of the toxin from the body. Both surgical and nonsurgical approaches may be useful, depending on the circumstances of an individual case.

Emollient cathartics (mineral oil or peanut butter) can be administered to aid in the passage of small particles of heavy metal out of the gastrointestinal tract. Other substances that have been used to aid in the passage of heavy metal particles include barium sulfate, psyllium and corn oil. The comparative effectiveness of these agents has not been determined. The use of sodium sulfate (Glauber's salts) has also been recommended for the removal of lead.¹⁶ Additionally, this agent can be mixed with activated charcoal and used following the ingestion of unknown toxins for its cathartic and absorptive effects. Sulfate will bind free lead in the gastrointestinal tract forming an insoluble lead sulfate that cannot be absorbed (mode of action similar to oral Ca EDTA and PA). Treated birds will generally develop diarrhea, and patients must be carefully monitored to prevent dehydration and severe electrolyte imbalances.¹⁶ The sodium sulfate is given as a slurry for up to two doses (in large birds) or until lead is gone from the gut. Aluminum sulfate is very irritating to the kidneys and is not recommended. Magnesium sulfate is not recommended as the released magnesium is depressing.¹⁶

An experimental chelating agent, dimercapto succinic acid (DMSA) has been found to improve survival

from lead poisoning by 35 to 50% when used in conjunction with CaEDTA in swans.^{6,35} This drug is experimental and requires a special FDA permit. The experimental dose is 25 to 35 mg/kg BID orally for five days per week for three to five weeks.

The administration of three to five appropriately sized pieces of grit may help in the removal of metal particles from the ventriculus by reducing their size²⁷ and facilitating passage, particularly when used in conjunction with psyllium (hemicellulose).⁴⁰

Activated charcoal is recommended to bind small lead particles in the gastrointestinal tract and make them unavailable for absorption. The small animal dose for activated charcoal is 2 to 8 g/kg body weight.⁴⁶ This should be gavaged as a slurry with water according to manufacturer's instructions. Activated charcoal will be inactivated if administered with mineral oil. Activated charcoal may be administered one to two hours before administration of a cathartic. This allows sufficient time for free heavy metals to be bound to the charcoal before the system is purged.

Endoscopic removal of heavy metal particles using appropriate forceps³⁰ or gastric lavage can be attempted in stable patients that are of sufficient size to tolerate this procedure.⁶ This technique is particularly effective when metal fragments in the ventriculus are too large to pass through the lower gastrointestinal tract in a reasonable period of time. Lead particles were removed from the gastrointestinal tract of swans by fasting eight to twelve hours followed by the insertion of a 110 cm tube into the ventriculus. The birds were tilted head down at a 45° angle and warm water was pumped into the ventriculus using a gastric lavage syringe.^c The contents were filtered through a towel to evaluate the number of particles removed. Radiographs of the head, neck and abdomen were used post-lavage to determine the presence and location of any remaining lead particles.⁶ Occasionally, a proventriculotomy may be necessary if other attempts to remove metal particles fail (see Chapter 41).^{56,72}

■ Zinc (Zn)

Zinc is another frequently encountered heavy metal that causes toxicity when ingested by birds. Zinc toxicosis should be included in the differential list when heavy metal intoxication is suspected. Galvanized wire and the clips used to construct enclosures are common sources of zinc. The clinical syndrome

described in birds that ingest zinc from a wire enclosure is frequently referred to as “new wire disease.”⁴⁰ The brighter and shinier the wire, the higher the zinc level.²¹ The occurrence of “new wire disease” can be reduced (but not eliminated) by scrubbing the wire with a brush and mild acidic solution (vinegar).⁵⁰ Galvanized wire may also contain lead.⁴⁰ Some galvanized coatings contain 99.9% zinc while others are 98% zinc and 1% lead. The white rust associated with the galvanized coating is also toxic.²¹ Galvanized containers and dishes are other sources of zinc contamination.²⁷ Pennies minted in the USA since 1982 contain from 96% to 98% zinc that is coated with copper.^{1,29,30,40} Monopoly™ game pieces are made of 98% zinc.¹

A duck from a zoological collection developed an acute onset of weakness and depression and died during examination. On necropsy, the ventriculus contained five tightly stacked, well eroded pennies. Some were minted after 1982. Pennies thrown into the duck’s pond by park visitors were the source of intoxication.

Common signs reported in zinc-intoxicated birds include polyuria, polydipsia, gastrointestinal problems, weight loss, weakness, anemia, cyanosis, hyperglycemia and seizures.^{28,30,50,68} Systemic effects are related to hypoproteinemia-induced damage in the kidneys, gastrointestinal system and pancreas.⁵² There are two cases of zinc depressing fertility, one in a male Mallard¹⁵ and one in a female Black Bustard.³⁰

Cockatiels fed the zinc coating from galvanized wire, or white rust from the same wire, developed clinical signs that included lethargy, weight loss, greenish diarrhea, ataxia, recumbency and death. This was the most common presentation in acute cases. A more chronic clinical course was characterized by intermittent lethargy, dysphagia and depression. Gross necropsy findings were limited to ileus. Histopathologic changes included focal mononuclear degeneration in the liver, kidney and pancreas.²¹

Serum concentrations of zinc can be used to confirm a diagnosis. Samples must be properly collected and stored to avoid extraneous contamination. Only glass or all-plastic syringes and tubes should be used for samples intended for zinc analysis. Rubber stoppers on serum tubes and the grommets on most plastic syringes can be a source of zinc contamination.³⁷ Serum tubes with royal blue-colored stoppers are free of zinc and are best for sample handling. A serum

sample collected from a clinically normal bird of the same species and handled identically will assist with interpreting results. In general, blood zinc levels of greater than 200 µg/dl (2 ppm) are considered diagnostic for zinc toxicosis.⁴⁰ In a group of normal cockatiels, the mean blood zinc level was found to be 163 µg/dl (1.63 ppm). The pancreas proved to be the best tissue for postmortem zinc level determination. Before exposure, the mean pancreatic zinc levels were 26.11 µg/g dry weight. The level in zinc-intoxicated birds ranged from 312.4 µg/g to 2418 µg/g.

Calcium EDTA is recommended as an effective chelating agent.^{27,30,40,52} D-penicillamine is also useful. Radiographically and clinically, zinc toxicosis cannot be differentiated from lead intoxication. Fortunately, the therapy is the same for poisonings caused by either of these heavy metals. The primary treatment involves removal of the foreign body. If a bird has ingested galvanized wire, this zinc-coated ferrous metal can be removed using a powerful neodymium-ferro-barium alloy magnet attached to a small diameter catheter with a removable, flexible steel grid wire (see Figure 19.13).³²

Fluoroscopy-guided removal is ideal; however, particles can also be removed by repeatedly passing the apparatus into the ventriculus until no further metal particles are removed. The success of the removal process can be determined with radiographs (Figure 37.4).³² Often, zinc foreign bodies can be removed with bulk cathartics (sodium sulfate), activated charcoal or mineral oil as described for lead. Gastroscopic removal using blunt-jawed forceps has been described.^{32,40} Surgical removal may be necessary if the object cannot be removed with other methods. It may be necessary to monitor packed cell volumes periodically if the bird is anemic.

Copper (Cu)

Factors that have been shown to affect the toxicity of copper in mammals include dietary zinc and molybdenum concentrations.⁴⁶ There are wide differences in how various animal species maintain copper homeostasis in the body, and birds appear to tolerate higher levels of copper than many mammals. Some reports have suggested that water contaminated with antifouling paints can be a source of copper intoxication in waterfowl.³⁹ Other sources of copper include copper wire, chronic over-supplementation in the diet, pennies minted before 1982 or any copper-coated objects small enough to be ingested. In a warm climate, copper sulfate used to control algae on a

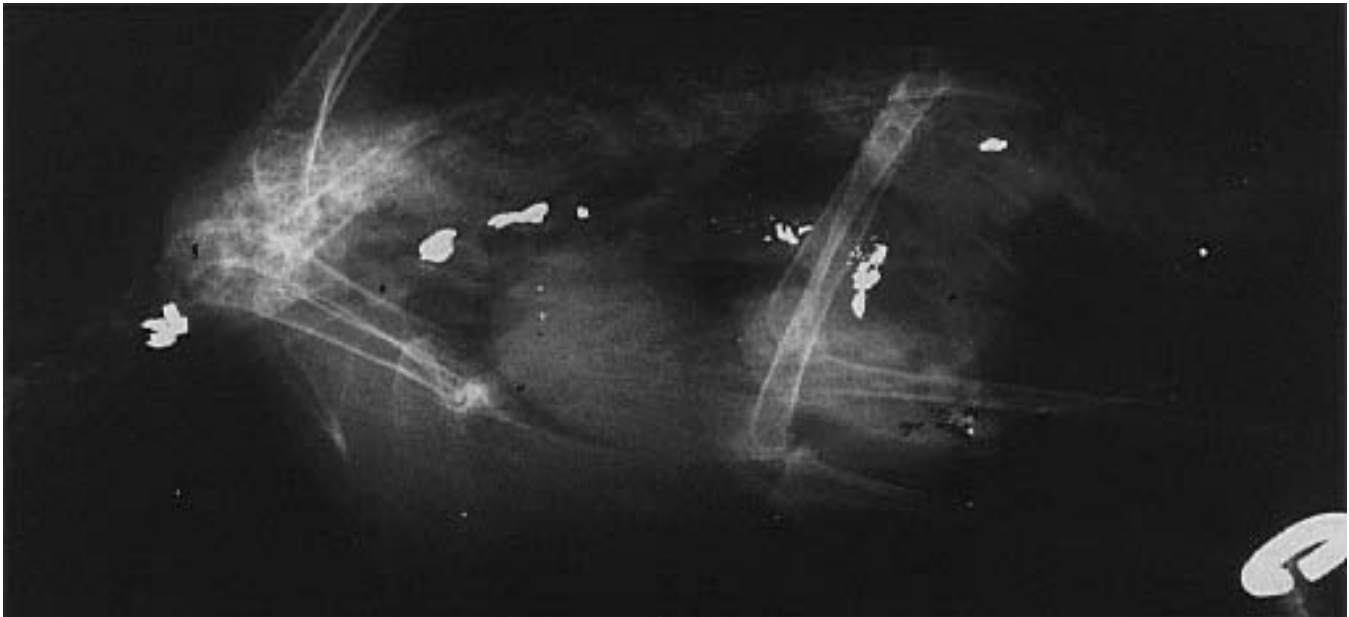

FIG 37.4 An adult Amazon parrot as presented with an acute onset of depression and regurgitation three days after a lead sinker was placed in the bird's enclosure as a toy. The metal in the crop, esophagus and proventriculus was removed either by endoscopy or gastric lavage. The bird was given oral D-penicillamine and a bulk laxative (psyllium). Response to therapy was excellent.

pond accumulated over time and caused the intoxication and death of swans.

Clinical abnormalities associated with copper intoxication have rarely been reported in birds. There have been reports of Mute Swans tolerating liver copper residues of up to 1000 mg/kg.¹³ A Mute Swan with inanition, anemia and generalized weakness showed signs of toxicity with liver copper levels in excess of 3000 mg/kg and over 50 mg/kg copper in the kidneys.¹³ Evidence of intravascular hemolysis (which is described in mammals) has not been documented in waterfowl.^{13,39} Postmortem findings following copper intoxication include anemia and coal-black discoloration of the liver (see Color 20).³⁹

D-penicillamine increases the renal excretion of copper and is the chelating agent of choice for copper toxicosis in mammals. In mammals, a dose of 52 mg/kg/day for six days has been recommended.⁴⁶ High-quality nutritional support is necessary to prevent chelation and removal of other vital minerals. Supportive care with fluids, warmth and minimal stress may aid in recovery. In severely anemic birds, blood transfusions may be necessary. In advanced cases the prognosis is poor.

Mercury (Hg)

Mercury poisoning is becoming an environmental concern as levels in water continue to rise. Fish

accumulate mercury, which is then further concentrated in fish-eating birds. An Amazon parrot that consumed the back of a mirror died following a period of profuse hematuria.³⁴ BAL (and presumably DMSA) and D-penicillamine chelate mercury.

Arsenic (Ar)

Polyuria, polydipsia, feather picking, pruritus, weight loss, dyspnea (air sacculitis), egg binding, poor feathering and death occurred in a group of aviary birds, presumably secondary to the consumption of arsenic-contaminated mineral block. Necropsy findings included cystic ovaries and adrenal gland enlargement. Clinical changes started when a new group of mineral blocks was used in the aviary. These blocks were found to contain 0.5% arsenic, and all clinical problems in the birds resolved when the mineral blocks were removed.⁶⁷

Oil

Crude oil is extremely toxic, and quantities of 0.3 μ l placed on the outside of eggs caused death in 50% of embryos; the embryos that survived had malformations of the eye, brain and beak. Generalized edema, hepatic necrosis, cardiomegaly and splenomegaly were noted also.⁴⁵



FIG 37.5 The pelletized fertilizers found on the surface of the soil in many house plants are more of a threat to companion birds than the houseplant itself. These encapsulated products contain high levels of nitrates that can be rapidly fatal (courtesy of Genevieve Dumonceaux).

Selenium

A dog shampoo containing selenium sulfide caused the death of a budgerigar.¹⁹

Nitrates

Nitrates are common components of fertilizers and may cause polydipsia, dyspnea, cyanosis and death following ingestion. The pelletized form of nitrate-containing fertilizers are particularly hazardous because they resemble seeds and may be readily consumed by birds (Figure 37.5).¹⁹

Plants

Clients are frequently concerned when a bird consumes a houseplant; however, plant intoxications are rare (Table 37.6). Free-flying companion birds frequently encounter and consume a variety of plants found in the home, few of which are at all toxic, some of which are thought to be toxic and some of which are of unknown toxicity. Determining the amount of plant ingested is always difficult, because birds seem to enjoy shredding leaves more than ingesting them. There have been few documented cases of plant poisonings in birds, and their rapid gastrointestinal transit time is thought to play a role in the low incidence of intoxication.

The ability of parrots to consume plants and fruits that are deleterious to other animals may have allowed these birds to reach their current widespread

TABLE 37.6 Poisonous Plant Cases Documented in Birds

Avocado	Psittaciformes (C,E)
Black Locust	Budgerigars (E)
Clematis	Budgerigars (E)
Diffenbachia	Canaries (E)
Foxglove	Canaries (E)
Lily of the Valley	Pigeons (C,E)
Lupine	Canaries (E)
Crown Vetch	Budgerigars, cockatiels, lovebirds (C)
Oleander	Budgerigars, canaries (E)
Parsley	Ostriches (C), ducks (E)
Philodendron	Budgerigars (E)
Poinsettia	Budgerigars (E)
Rhododendron	Budgerigars (E)
Virginia Creeper	Budgerigars (E)
Yew	Pheasants (C), canaries (E)

C = clinical report; E = experimental

The state of an animal's health should be expected to have an impact on its response to ingested plants. The experimental doses used to demonstrate that some of these plants were toxic are not likely to occur in natural settings.

distribution in the wild.⁴² It has been proposed that parrots can consume toxic plants because they carefully remove the outer covering, which frequently contains the highest concentration of toxins. Alternatively, it has been suggested that the consumption of clay by free-ranging birds may serve to absorb some toxic materials and prevent them from passing through the gastrointestinal mucosa. However, many birds consume potentially toxic plants and only macaws have been observed consuming clay. It is more likely that the ingested plant material is eliminated before dangerous levels of the toxic component can be systemically absorbed.¹² The Cedar Waxwing and the House Finch can safely consume fruit from the pepper tree (*Capsicum annuum*) that is toxic to mammals.⁴³

In one study, yew, oleander, Virginia creeper, black locust, clematis and avocado⁵⁹ were described as toxic to budgerigars when administered by gavage. Many other plants that were tested had no harmful effects under the same testing conditions. In another study, oleander, lily of the valley, rhododendron, poinsettia and philodendron were not found to be major health hazards for budgerigars.¹²

In a similar study involving canaries, oleander, lupine, foxglove, yew leaves and diffenbachia were considered to be highly toxic. Nine other plants that have traditionally been considered toxic (parsley, hoyia [wax plant], rhododendron, black locust, wis-

teria, clematis, cherry, pyracantha [fire thorn] and privet) caused no, or only transient, clinical problems. Most canaries that died did so within minutes to hours following the ingestion of the plants.²

Split-leaf philodendrons have been used in some aviaries in Florida for years with no signs of toxicity. However, in one case, two Amazon parrots that destroyed a large split-leaf philodendron had a two-hour course of lethargy and vomiting followed by complete, unsupported recovery.

Cherries, plums and peaches (*Prunus* spp.) have pits containing seeds that produce cyanogenic glycosides; however, there are no reports of cyanide poisoning in birds following the ingestion of these fruits. It has been suggested that cyanide poisoning may be more common in ruminants because of a rapid enzymatic degradation of the glycoside to free cyanide. Alternately, detoxification may be more effective in simple-stomached animals.¹²

Avocados (*Persea* spp.) have recently been suggested as toxic for companion birds. At one time it was believed that only the pit was a danger; however, some studies suggest that all parts of the avocado, including the fruit, are toxic to birds.^{5,18} The toxin in the avocado has not been described.⁵ There are several varieties of avocados commercially available (eg, Guatemalan, Mexican, Nabal and Fuerte), which appear to differ in their toxic capacity. In one study involving rabbits, the Guatemalan and Nabal varieties caused death from pulmonary congestion within 24 hours after ingestion.⁵ The Mexican variety was nontoxic.⁵

Signs of avocado toxicity (Guatemalan and Fuerte varieties) in budgerigars and canaries include cessation of perching, anorexia, fluffed feathers, increased respiratory rate, outstretched wings and death. At necropsy, intoxicated birds are in good overall condition, and the crop and ventriculus may be full of ingesta, indicating the acute nature of the toxicity. Subcutaneous edema of the pectoral region has been reported in some affected birds, and others will have pectoral muscles that bulge slightly above the sternum with mild pale streaks running parallel to the muscle fibers. Histologic lesions have been limited to generalized congestion, especially in the lungs.¹⁸

To the authors' knowledge, a specific treatment regimen for avocado intoxication in birds has not been established. Based on clinical signs and postmortem findings, activated charcoal and general supportive measures such as oxygen, warmth and perhaps a

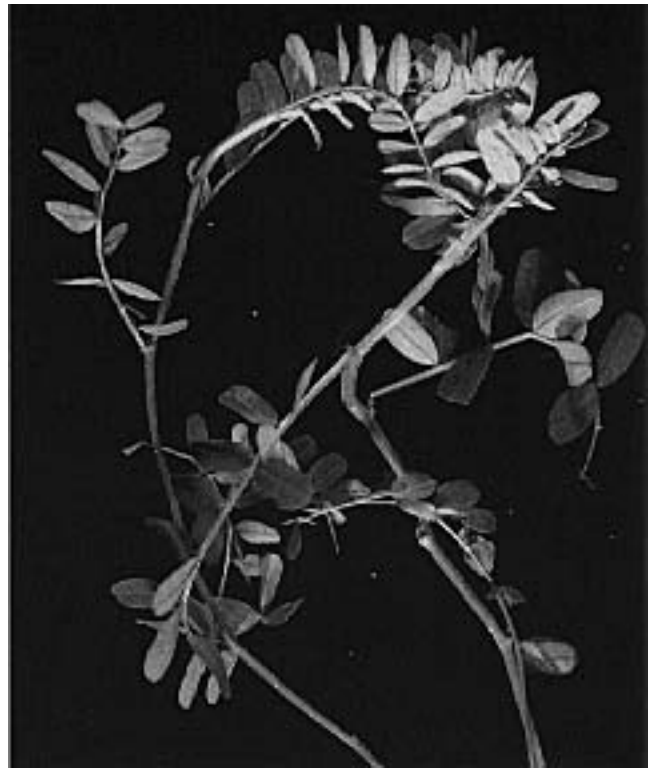

FIG 37.6 Crown Vetch ingestion has been associated with tremors, opisthotonos, seizures and death in budgerigars, cockatiels and lovebirds (courtesy of Michael Lutz).

mild diuretic may be indicated. Birds have been reported to die as soon as 9 to 15 hours after consuming avocado. Some birds died within 10 to 15 minutes after developing signs of respiratory distress without prior clinical signs.¹⁸

Budgerigars, cockatiels and lovebirds developed tremors, opisthotonus and seizures twelve hours after consuming crown vetch (Figure 37.6). Eighty percent of the birds with clinical signs died despite treatment. Deaths in the flocks reached 10% until the plant was removed, and no further losses were reported.³³ The inciting toxin was not confirmed, but may be a cyanide.

Oak toxicosis (coast live oak - *Quercus agrifolia*) was confirmed in a cassowary that consumed the leaves. Clinical changes included anorexia, ataxia, diarrhea, severe polydipsia and death. Necropsy revealed diffuse serosal hyperemia, ulcers and hemorrhage in the small intestine. Liver tissue and gastric contents tested for tannins showed levels of 178 and 340 ppm respectively, which supported the diagnosis of oak toxicosis.²³

Rape seed has been suggested as a hepatotoxin; however, canary breeders routinely feed soaked rape seed to breeding canaries and their offspring without a problem. Parsley has been shown to cause photosensitization and skin lesions in ostriches and experimentally in ducks.⁴⁴

■ Mycotoxins

Mycotoxins are chemical metabolites produced by various species of fungi that grow on grains and foodstuffs. Each fungus has its own light, temperature and moisture requirements.⁷⁴ Some of these fungi grow on crops in the field during periods of high moisture content (*Fusarium* spp.). Others grow on foods during storage, when moisture contents are relatively low (*Aspergillus* spp.). Aflatoxin production can be decreased by storing food in a low-oxygen, high-CO₂ environment. In areas of the southern United States, where the preferred conditions for aflatoxin production are common (25-30°C, humidity 85%), refrigeration of food is often necessary to prevent aflatoxin production.

The conditions that induce a fungus to produce toxins may be different than those needed for fungal growth; therefore, the fungus can grow without toxin production. Likewise, the toxin can be present after the fungus has stopped reproducing. Clinically, this means that the presence of a fungus on a foodstuff does not necessarily indicate that a toxin is present, nor does its absence mean that food or grain is free of mycotoxins.

The amount of toxin present can vary within any given batch of grain or feed. Depending on the storage methods and size of the stored sample, one area may have no detectable mycotoxin, while another may have a very large concentration (known as a “hot spot”). Attempts to determine if mycotoxins are present using ultraviolet light are of little value, because both false-positive and false-negative results are common.

Toxins can enter an avian host through surface-to-skin contact. The effects of mycotoxin exposure can vary based on the type of toxin and on the species, nutritional state and physiologic status of the patient. A stressed bird or one on a poor diet is more likely to be poisoned by a lower dose of mycotoxin than is a healthy, well-fed bird. Ducklings have been shown to be much more sensitive to aflatoxin than chicks, indicating species variance in sensitivity.⁴¹

There are no specific antidotes for mycotoxicoses. It is easier to prevent exposure to mycotoxins than to attempt treatment following their ingestion. All foods and seeds available to birds should be clean and fresh. Foods that are dusty, damaged by insects or have molds present should not be offered to birds. Particular caution should be exercised with poor quality corn and peanuts, as these are common sources of toxin-producing molds. Some high-quality formulated diets are certified free of mycotoxins. Treatment involves providing clean food free of molds, supportive care, broad-spectrum antibiotics and specific therapies for clinical signs.

There are four main mycotoxins of concern to birds: aflatoxin B₁, ochratoxin A, deoxynivalenol (vomitoxin) and the trichothecenes, especially T₂ toxin. These are all potent mycotoxins that affect different body organs or systems. The molds producing these toxins can grow on various foods, including grains, peanuts and peanut products, breads, meats, cheeses and cereal grains. Whole kernel peanuts of apparently good quality can harbor high concentrations of aflatoxins.⁷⁴ Brazil nuts are banned in Austria because a mycotoxin-free nut was not available (Hochleithner M, unpublished). Diagnosis is based on clinical signs, postmortem and histopathologic findings, and detecting high quantities of the toxin in the gastrointestinal contents or the food. However, it is difficult to establish a diagnosis of mycotoxicosis in birds. Clinical and histologic changes usually mimic other diseases or may be due to secondary infections. Often, by the time signs are apparent, the toxin-contaminated food source has already been consumed and is not available for evaluation.

Aflatoxin B₁ is a known hepatotoxin. It is produced by *Aspergillus* spp. and may cause depression, poor growth, anorexia and other signs related to liver disease. Postmortem changes include an enlarged, pale liver (probably the result of fatty infiltration), an enlarged spleen, an enlarged pancreas, atrophy of the cloacal bursa and less-than-normal body fat deposits (see Color 20).⁶¹

Aflatoxins inhibit protein and nucleic acid synthesis. Microscopic examination shows hepatic cell degeneration and bile duct hyperplasia. The kidneys may have swollen proximal convoluted tubules.⁴¹ Anticoagulant activity is altered, and a bird with a prolonged whole blood clotting time and prothrombin time may be suffering from aflatoxicosis. Gastrointestinal hemorrhage is also common. Immunosuppression through a reduction in alpha and beta

globulins has also been linked to aflatoxin exposure. Serum electrophoresis to detect this IgG pattern may be useful in diagnosing aflatoxicosis.

The trichothecenes, including T₂ toxin, are produced by *Fusarium* spp., which commonly grow on crops in the field. This toxin has corrosive effects on the mucous membranes of the oropharynx, and occasionally the gastrointestinal tract, causing necrotic lesions of the hard palate and other oral areas. Lesions can appear within 48 hours of ingestion.⁵⁸ Trichothecene intoxication in Sandhill Cranes caused signs including flaccid paralysis of the wing and neck, depression and flying with the head and neck perpendicular (in those birds that could fly). These birds were exposed to waste peanuts that contained high levels of trichothecenes.⁷¹ Peanut farmers are encouraged to plow ground containing waste peanuts to prevent their consumption by free-ranging birds, particularly Sandhill Cranes.

Trichothecene T₂ toxin may also cause contact dermatitis (from contaminated litter), poor growth and feathering, constrictive lesions of the digits (dry gangrene) and occasionally neurologic disorders.^{71,73} In one study, a high incidence of T₂ toxin was reported in grains heavily damaged by insects.⁴

Histopathology of affected birds may reveal congestion and hyperemia of the gastrointestinal tract, hemorrhagic myositis, hepatic and renal swelling and congestion.⁷¹ In chronic cases, evidence of secondary infections may be noted.

Ochratoxin is produced by species of *Aspergillus* and *Penicillium* fungi. The toxin has an immunosuppressive effect and has been associated with air sacculitis, nephrotoxicity, CNS signs, hepatotoxicity and bone marrow suppression. It has been shown to cause depression of the immunoglobulin-containing cells in the lymphoid organs.⁹ Clinical changes are commonly related to secondary infections that take advantage of a depressed immune system.



FIG 37.7 Birds should not be allowed to consume high-salt foods, chocolate in any form or alcoholic beverages (courtesy of Genevieve Dumonceaux).

Ethylene Glycol

Free-ranging birds may consume ethylene glycol. In gallinaceous birds, consumption of antifreeze has been associated with lethargy, ataxia and polyuria. Characteristic calcium oxalate crystals form in the kidneys.²⁸

Harmful Foods

Clients frequently share favorite foods with their companion birds; however, some of these treats can be life-threatening through a single or chronic exposure. Chocolate is contraindicated as a treat for any pet, including birds. Consumption of small quantities of chocolate can result in hyperactivity, vomiting, diarrhea, cardiac arrhythmias, seizures, dark-colored feces and death. The progression of these effects can be rapid when large concentrations of the active ingredients (theophylline and caffeine) are ingested. A rule of thumb for chocolate toxicity is that the less sugar that is present, the more of the toxic active ingredients there are in the product. It is best to avoid feeding any type of chocolate to birds (Figure 37.7). Treatment for chocolate toxicosis includes the administration of gastrointestinal protectants and cathartics.

Excessive consumption of sodium chloride can cause polydipsia, polyuria, depression, neurologic excite-

ment, tremors, opisthotonos, ataxia and death. Necropsy changes are generally limited to cerebral edema and hemorrhage.²⁸

Consumption of alcoholic beverages can lead to severe ataxia and death. Additionally, birds may become intoxicated if compounds containing high levels of ethanol (STA) are used to clean open wounds.

Iatrogenic Intoxications

Properly administered medications can be life-saving; however, many drugs have a low therapeutic index, and the safest of drugs may be toxic in excess quantities. Pre-existing systemic disease, nutritional status, state of hydration, drug interactions, carrier agents and species-specific idiosyncracies of a particular therapeutic agent should all be considered before initiating drug therapy (see Chapter 18). The most common cause of iatrogenic drug toxicosis is a failure to base the dose on an accurate weight. A dosing table^d that can be used to quickly and accurately determine drug dosages is commercially available.

There are only a few therapeutic agents approved for use in birds; however, many drugs approved for other species can be beneficial in the treatment of sick and injured avian patients. Administering drugs at the proper dose, at an appropriate time interval, through a recommended route of administration and with consideration for patient-specific contraindications will minimize the potential for iatrogenic intoxications.

Some drugs given parenterally at the appropriate dosage (especially IM) can cause various degrees of local tissue damage (see Figure 17.4). Many of these reactions can be attributed to the carrier in the formulation. Injectable products that contain propylene glycol (PG) or oil as a carrier may cause an abscess or toxic reaction. Oral consumption of propylene glycol has not been reported to cause acute signs of toxicity, but the long-term effects of PG used as a food preservative have not been studied in birds. In cats, ingestion of PG can cause anemia. Ethoxyquin is another food preservative that may have unreported toxic side effects. This compound was originally used

as a herbicide, and there have been some discussions that it may cause reproductive abnormalities in dogs.

Anthelmintics

Ivermectin in a PG base may cause toxic reactions when administered IM to budgerigars. Oral or topical administration is safer and equally efficacious. Ivermectin that is diluted in PG and allowed to stand should be mixed thoroughly before administration. Oral administration of a product that was not shaken caused seizures in several canaries and budgerigars. High-dose steroids reversed the clinical signs in these cases. Ivermectin persists in the environment and is excreted unchanged in the urine. Low concentrations that accumulate in water are extremely toxic to crustaceans, and whales may be particularly sensitive to this drug.

Dimetridazole was shown to have a low therapeutic index when added to the drinking water of cockatiel chicks. In nestlings (one to eight days old), the recommended concentration of 0.1% dimetridazole in the drinking water caused signs of toxicity including weakness, depressed growth rates, tremors and death. Older nestlings (over eight days old) showed no signs of toxicity at 0.1% concentrations.

At 0.5% dimetridazole, older birds developed signs of ataxia, weakness, inactivity, tremors, extensor rigidity of the legs and necks, and death. Consistent necropsy findings included multiple hemorrhages, pale livers and enlarged, pale kidneys. Treatment of adult cockatiels at the recommended dose appears to be safe. Dimetridazole should not be used in the drinking water during the breeding season when males may consume excess quantities of the drug and feed it to nestlings, causing toxicosis and death.⁶⁰

Vetisulid and some other sulfa-containing antibiotics have been reported to cause hypersensitivity reactions leading to a hemorrhagic syndrome in gallinaeous birds.¹⁷ They may also interfere with renal tubular excretion and are contraindicated in dehydrated or uricemic patients.¹⁰ These antimicrobial agents should be limited in use to sensitive bacteria and the treatment of coccidiosis.¹⁷

Levamisole hydrochloride (oral) and levamisole phosphate (injectable) have been used to treat intestinal parasites in birds. Side effects associated with these agents in Psittaciformes and Galliformes include regurgitation, ataxia, recumbency, catatonia, dyspnea and death. Effects are immediate, and sur-

viving birds are clinically normal within one hour after administration. The dosage range used to study toxic effects in birds was 22-100 mg/kg. A dose rate of 22 mg/kg was considered effective for some parasites and was well tolerated by many genera of aviary birds.⁵⁴ Regurgitation is the most common side effect associated with oral levamisole administration, and food and water should be withheld for several hours prior to dosing.

The parasiticides praziquantel and fenbendazole have been reported to cause problems in finches and pigeons ranging from feather malformations to vomiting and death.

Antibiotics

Aminoglycosides have a narrow therapeutic index and are nephrotoxic. Gentamicin causes severe renal tubular necrosis and is the most frequently discussed member of the group. Systemic, topical and ophthalmic canine products can cause nephritis and are generally contraindicated in all companion birds. Amikacin is a safer alternative when an aminoglycoside is indicated. Renal function should be monitored during treatment. Administration of aminoglycosides into the leg is generally avoided due to the renal portal system of birds. It is speculated that drug administration in the leg muscles may cause excessive renal concentrations of the aminoglycoside, increasing the potential for nephrotoxicosis. If an intoxication is suspected, the antibiotic should be discontinued and diuresis with physiologic saline should be initiated immediately.

Tetracyclines, cephalosporins (especially cephaloridine) and amphotericin B⁴⁸ may also cause nephrotoxicosis in patients with impaired renal function.

Procaine penicillins have been associated with some toxic reactions in birds (see Chapter 18). A South American Black-collared Hawk experienced vomiting and acute collapse following an intramuscular injection;⁴⁸ however, this class of antibiotics is still considered effective and indicated in many bacterial infections. Vomiting may be noted following the IM or oral administration of doxycycline.

The popularity of enrofloxacin has been increasing in avian medicine because of its broad spectrum of activity and its good tissue penetration. Abnormalities in articular cartilage have been reported in squabs dosed at 800 ppm. Only one chick was affected at a dose of 200 ppm. Enrofloxacin was not shown to

cause clinically recognizable joint abnormalities in a group of psittacine birds from a large aviary.^{3,26}

Chloramphenicol, penicillin, tetracycline, oxytetracycline and sulfa drugs may cause deformities in embryos and should not be used in hens near or during the breeding season.⁴⁵

Antifungals

Antifungal agents can have serious side effects, particularly with prolonged use. Amphotericin B has been associated with acidosis, azotemia, vomiting, seizures, hypokalemia, hepatic dysfunction, anemia, anaphylaxis and nephrotoxicosis.⁴⁸ Flucytosine may cause bone marrow depression, anemia, thrombocytopenia and leukopenia. Decreased renal function may precipitate gastrointestinal signs and elevate liver enzymes.⁴⁸ Amphotericin B used as a sinus flush caused a severe granulomatous reaction in an African Grey Parrot resulting in death.⁶⁶ The toxic side effects of these drugs should be considered when treating a bird for a fungal infection, and these agents should be used only when specifically indicated.

Hypervitaminosis

Increased awareness of the nutritional needs of birds and the availability of formulated diets and numerous dietary supplements have created problems associated with the consumption of toxic levels of some nutrients. Of particular concern are vitamins A, D₃ (cholecalciferol) and calcium. Many formulated diets contain excess quantities of these nutrients, and further supplementation of these diets with vitamin and mineral products can result in life-threatening toxicities.

Hypervitaminosis A can cause osteodystrophy characterized by thickening of the proliferative-maturation zone, metaphyseal sclerosis, hyperosteoidosis and decreased numbers of osteoclasts. Parathyroid gland hyperplasia can also occur (see Color 14).⁶³ Hypervitaminosis D₃ can cause mineralization of parenchymal organs including the liver, kidneys, stomach, intestines, heart and blood vessels.⁶⁴ High levels of vitamin D₃ cause an increase in serum calcium levels, which may affect cardiac conduction and smooth muscle contractions.⁸ Renal calcification in macaws and African Grey Parrots suggests that they may be particularly sensitive to hypervitaminosis D and excess calcium consumption.⁶⁴ Excessive calcium

can lead to skeletal abnormalities, especially in developing chicks (see Chapter 3).

A thorough dietary history must be included in the general history of any patient presented for evaluation. Vitamin injections are often used in debilitated birds. If the patient has been on a formulated diet or over-supplemented previously, parenteral administration of a multivitamin preparation may cause or exacerbate a vitamin intoxication problem.

The formulation of the injectable supplement used is important. Injacom 100 is the injectable vitamin supplement recommended for use in birds. It is water-soluble and contains 100,000 IU vitamin A and 10,000 IU vitamin D₃ per milliliter. Regular Injacom is an oil-based product containing five times as much vitamin A and 7.5 times as much Vitamin D₃, which increases the potential for toxicosis when administered to birds.

Airborne Toxins

The avian respiratory system is more efficient than that of mammals. The disadvantage to this efficient system is that it readily extracts harmful gases and particles from inhaled air, increasing a bird's sensitivity to inspired toxins. Administering 100% oxygen to birds for more than 12 hours was found to be fatal with death occurring in four to eight days; exposed birds appeared stressed and uncomfortable as early as three days post-exposure.⁶²

Polytetrafluoroethylene Gas

Polytetrafluoroethylene (PTFE) gas, released when various non-stick surfaces such as Teflon® overheat or burn, is a common respiratory toxin in birds. Potential sources of PTFE gas exposure include non-stick cookware, drip pans, irons, ironing board covers, the heating elements of some reverse-cycle heat pumps and heat lamps. As these surfaces are heated to above 530°F (280°C), they undergo pyrolysis and PTFE is degraded releasing irritant particles and acidic gases.^{69,70}

The lungs are the target organ for PTFE poisoning in birds. Clinical signs are usually limited to sudden death, but depending on the degree of exposure may

include somnolence, dyspnea, wheezing, incoordination, weakness, respiratory distress and terminal convulsions.^{69,70} Death usually occurs too rapidly for treatment to be initiated.

Hemorrhage and congestion of the lungs are the usual postmortem findings (see Color 22).^{69,70} These lesions are thought to be caused by exposure of the respiratory epithelium to inhaled acidic gases.⁷⁰ Occasionally, PTFE particles may be recognized histologically in some lung sections.

With minimal exposure, birds may respond to immediate transfer to fresh air, coupled with the administration of intratracheal and systemic steroids, broad-spectrum antibiotics, fluids and a warm environment to prevent shock, pulmonary edema and bronchopneumonia.

Tobacco Products

Birds should never be allowed to consume tobacco products. Ingestion of small quantities of nicotine can cause hyperexcitability, vomiting, diarrhea, seizures and rapid death. Treatment is supportive and symptomatic.

Passive inhalation of cigarette, cigar and pipe smoke can cause chronic ocular, dermatologic and respiratory disease in companion birds (see Chapter 22). Birds that live in homes with smokers will often present with clinical signs including coughing, sneezing, sinusitis and conjunctivitis due to continuous irritation of the respiratory system. The clinical signs may resolve without treatment if no secondary infectious agents are involved, the clients stop smoking or the bird is placed in a location where there is no smoke. Secondary bacterial invasion of the damaged respiratory epithelium is common and requires therapy; however, therapy for these infections will be of little value if the bird is continuously exposed to smoke.

In order to keep pet birds healthy, they should be maintained in well-ventilated, smoke-free environments (Ritchie, BW unpublished). Exposure to secondary smoke from marijuana can cause severe depression and regurgitation and should be strictly avoided.

Nicotine sulfate has been shown to cause severe skeletal malformation, reduced body weight, torticollis, edema, muscular dystrophy and malformation of the beak, heart and kidneys.⁴⁵ Pododermatitis has been observed in some birds handled by people who smoke routinely. Repeated exposure to the nicotine

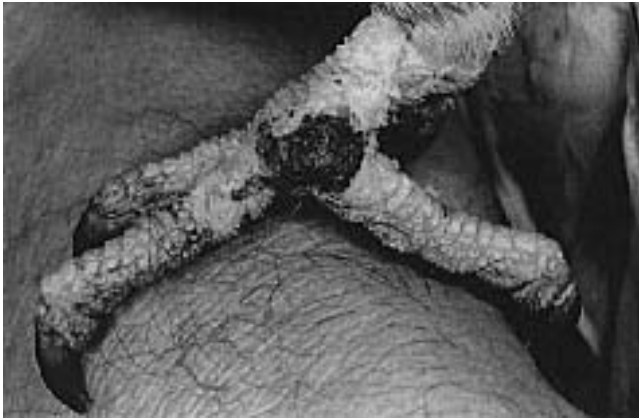

FIG 37.8 An adult Amazon parrot was presented with a ten-day history of progressive picking at the feet with scab formation. The bird was fed a formulated diet supplemented with some fresh vegetables. The feet were hyperemic and the feathers were dull and appeared tattered, particularly at the ends. The bird had mild epiphora and a serous nasal discharge. Both adult clients were heavy smokers. The bird's ocular, respiratory and foot problems resolved when the clients stopped smoking in the house and washed their hands before handling the bird.

residues on the hands of smokers is thought to cause this local irritation (Figure 37.8). Macaws may suffer a similar dermatitis on the bare cheek patches following repeated contact with a smoker's hands. Many birds with severe feather picking problems will resume normal preening behavior when removed from exposure to cigarette smoke (Ritchie, BW unpublished).

Disinfectants

Disinfecting agents used to clean enclosures and food dishes should be used cautiously in aviaries and where companion birds are housed. Hatchlings and nestlings are especially prone to respiratory problems associated with chronic exposure to disinfectants or their fumes. A standard drain opener that contains sodium hypochlorite produced fumes that killed a Goffin's Cockatoo, African Grey Parrot and a cockatiel within minutes after a Clorox solution was also poured into the sink.

Irritation and dermatitis may occur following contact with many concentrated cleaning solutions (phenols, chlorhexidine and chlorine). All enclosures, nest boxes or aviary tools that are placed in disinfectants should be thoroughly rinsed with clean water before they are in contact with a bird.¹¹

Direct contact between the bird and cleaning solutions should be avoided. If contact occurs, the area should be rinsed copiously with sterile saline. Appli-

cation of antibiotic creams and bandaging may be necessary in some cases. When ingestion of cleaning products or disinfectants occurs, the manufacturer's recommendations for therapy should be followed. If recommendations are not available, then birds ingesting non-caustic materials should be treated with a mild laxative to speed passage of the solution out of the body. Gentle gavage or flushing is indicated if a corrosive material has been ingested to prevent perforation of the esophagus or crop.¹¹ Corrosive materials require immediate dilution with water. Eyes or skin areas exposed to corrosives must be rinsed with clean water for at least twenty minutes. Systemic poisoning must be treated symptomatically, as there are no antidotes for disinfectant intoxications.

Ammonia and bleach are frequently used in household cleaning, and fumes from these products are commonly encountered by companion birds. Ammonia can be absorbed into the circulation by inhalation. In some species, increased blood ammonia concentrations have been shown to reduce lymphocyte function and alter their mitogenic activity resulting in a decreased cellular and humoral immune response. One study showed that blood ammonia concentration in excess of 1 mg/dl was an indication of toxicity. Even subtoxic concentrations (<1 mg/dl) in birds can predispose them to infectious diseases (see Figure 5.3).²⁴

Ammonia and chlorine vapors can also irritate the epithelial linings of the eyes, conjunctiva, nares and respiratory tract. The resulting inflammation and damage can predispose these surfaces to secondary bacterial and fungal infections. Severe inflammation from exposure to strong concentrations of ammonia may impair respiration. Treatment consists of oxygen therapy, steroids to reduce inflammation and broad-spectrum antibiotics to combat secondary bacterial infections.

Miscellaneous Aerosols

Common household aerosol products such as perfumes, deodorants and cleaning agents may cause respiratory problems in birds. These problems arise from direct irritation of the respiratory tract by the fluorocarbons and particulates in these aerosols. The most common effect is inflammation and edema of the respiratory tract leading to dyspnea. In severe cases, death may occur shortly after a large or direct exposure. It is the authors' recommendation that aerosol sprays not be used in areas where companion birds may be directly exposed, and definitely not

sprayed directly on the bird. Formaldehyde fumes have been associated with epiphora, dyspnea and death in canaries (see Figure 5.3).¹⁹ An ozone generator caused the deaths of some birds in a pet shop. A cockatoo that was in the same room where a suede protector was used developed dyspnea within two hours, and died five hours after being exposed to the fumes from this product.

Leaks in natural gas lines may cause subtle respiratory signs in birds, even when no odors are detected by the clients. With more serious leaks, sudden death can occur. When birds are presented with respiratory problems or weakness of unknown etiology, careful questioning concerning the home environment may help determine if a leaking gas line could be a contributing factor. Kerosene fumes may also be toxic to birds, and combustible space heaters should not be used in homes containing companion birds.

Carbon monoxide (CO) is an odorless, colorless, tasteless gas produced by combustion engines and some furnaces. Birds maintained in poorly ventilated, heated areas, or transported in poorly ventilated vehicles (especially in car trunks) are at high risk of CO poisoning. Carbon monoxide competes with oxygen for hemoglobin binding sites in the blood. The affinity of hemoglobin for CO is about 250 times greater than its affinity for oxygen in mammals. Binding of CO to hemoglobin decreases the ability of oxygen to dissociate from hemoglobin, resulting in hypoxia. Carbon monoxide poisoning can occur when birds are placed in a confined area where the gas cannot escape.

Birds suffering from CO poisoning may die acutely and have bright red, apparently well oxygenated blood and pink- or red-colored tissues. Other signs of CO poisoning include depression, somnolence and dyspnea.

If CO poisoning is suspected, fresh air should be provided immediately, and emergency care should include the administration of 90 to 95% oxygen in a cool, dark, stress-free environment. Oxygen toxicosis can occur if a bird is exposed to O₂ levels of 90% to 100% for prolonged periods.⁶²

Pulmonary silicosis caused chronic dyspnea and death in a Blue and Gold Macaw. The bird was exposed to the silicone through peat moss used as nesting material. In humans, a silicone/sulfur ratio of over 0.3 is considered indicative of silicosis. The ratio in this Blue and Gold Macaw was 9.07.⁴⁹

Grossly, this bird's lungs appeared necrotic, and unencapsulated pyogranulomatous nodules that contained deposits of pale, amphophilic, refractory crystalline material that displayed birefringence when exposed to polarized light were seen histologically. Similar toxicities have been described in a rhea, ostrich, turaco, swan, owl, crane, duck, kiwi and Ring-neck Pheasant.⁴⁹



Insecticides

Exposure to high concentrations of pesticides can lead to nonspecific signs of poisoning including gastrointestinal problems, tremors, weakness, dyspnea, seizures or sudden death. Chronic low-grade exposure to pesticides may induce more subtle clinical signs that are more difficult to attribute to a toxin exposure. These exposures may cause immunosuppression and increased susceptibility to disease, decreased reproductive activity or generalized unthriftiness (Figure 37.9).

The most commonly used household insecticides contain pyrethrins, carbamates and organophosphates. While pyrethrins and carbamates are occasionally used as pesticides in association with birds, these agents are nonetheless toxic, especially following inhalation or contact with high concentrations. Pesticides may be absorbed through the skin following secondary contact with treated surfaces. Additionally, many insecticides contain carriers that can be irritating to the skin and respiratory tract mucosa.¹¹ Ingestion of foods contaminated with common agriculture pesticides could be a source of intoxication in birds. All grain products, fruits and vegetables that are not certified organic have levels of pesticides that have been determined to be acceptable ("safe" is a relative term) for human consumption. The effects of constant exposure of birds to these toxins has not been determined.

If absolutely necessary, dusting powders containing pyrethrins or carbamates (eg, 5% Sevin) can be used with some margin of safety on birds.¹¹ These compounds are not absorbed through the skin and are more likely to penetrate the feathers than sprays; however, excessive preening (ingestion) or inhalation of the dusts can lead to systemic intoxication that is dose-related.

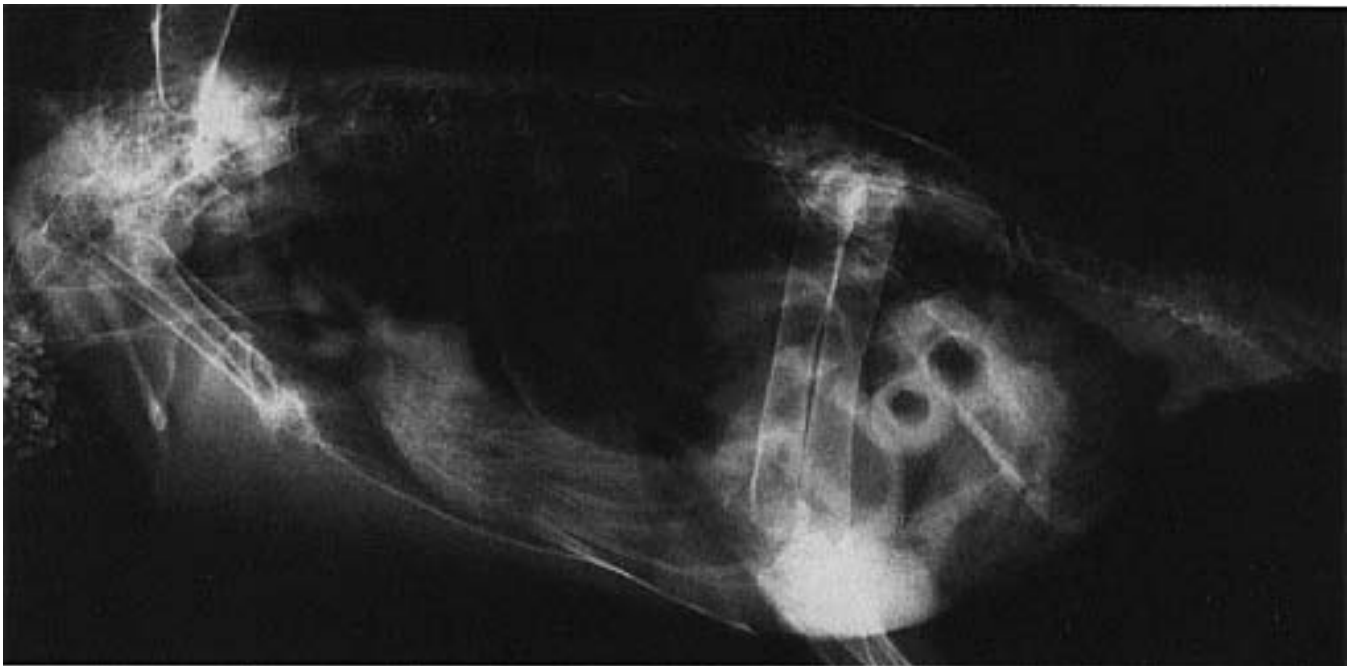


FIG 37.9 A Scarlet Macaw that was housed ten feet from a cyclic (every 30 minutes) pyrethrin mister was presented for regurgitation and severe weight loss (590 g). Radiographs indicated ileus, microcardia and microhepatia. Note the gastric distension of an empty cranial gastrointestinal tract and a full crop. The bird did not respond to supportive care. A perforating proventricular ulcer and liver cirrhosis were demonstrated at necropsy (see Color 19).

Clients can minimize a bird's exposure to insecticides by providing clean water and residue-free foods. If fresh fruits and vegetables are provided, they should be thoroughly rinsed in clean water to remove any insecticides used by the grower. Care must be exercised when pesticides and other volatile chemicals are used in and near a bird's area. Any materials used for perches should be thoroughly scrubbed and rinsed before being placed into the bird's enclosure.

Most potential contaminants are difficult to detect, and it is best to err on the side of caution. The effects of modern petro-chemicals on companion birds can only be postulated using the statistics that suggest their impact on the declining migratory bird populations in North and South America.

■ Organochlorines

The use of some organochlorines (DDT and DDE) have been banned in the United States and other countries, yet reports of poisoning in native species persist.⁴⁷ Migratory birds may be exposed in other countries that still use DDT produced in the United States. Poisoned birds may develop signs of convulsions, blindness (pupils may or may not respond to light), ataxia, anemia and hypoproteinemia. Gas

chromatography can be used to determine tissue concentrations of these compounds.⁴⁷

■ Organophosphates

Clinical signs of organophosphate toxicity are caused by inhibition of acetylcholinesterase. Organophosphate poisoning in raptors appears clinically different than is typically described for mammals. Raptors are frequently contaminated by consuming poisoned starlings or grackles.⁴⁷ Clinical signs include ataxia, spastic nictitans, a detached attitude, inability to fly and occasionally convulsions. If present, convulsions are characterized by rigid paralysis, tightly clinched talons, rapid respiration, alivation, twitching of muscles and anascaria.

Scoliosis, lordosis (shortening or contortion of the axial skeleton) and severe edema were described in embryos exposed to parathion. Diazinon caused incomplete ossification and stunting. Carbaryl, methomyl and permethrin were considered relatively nontoxic to embryos.⁴⁵

Dichlorvos (DDVP, Vapona) is a commonly used organophosphate that is impregnated in insect repellent strips. It is best for birds not to be exposed to any inhaled toxins; however, if a dichlorvos insecticide

must be used, it should be placed in a well ventilated room of appropriate size. Direct oral exposure should be avoided. Smaller species (eg, canaries, finches) are more sensitive to the pesticide vapors than budgerigars and larger psittacine birds.¹¹ In addition, higher ambient temperatures increase the risk of intoxication.¹¹ Other sources of avian exposure to organophosphates include flea collars, contaminated fruit limbs and frequently treated baseboards. There have been reports of birds being poisoned by consuming food that was stored in containers in which dichlorvos strips had been placed to control insects. A mite protector (para-chlorometazymol) placed in a container of finch seeds was thought to have caused the death of a finch. Seven of 15 canaries and finches died when moth balls were enclosed in a container that held their seed mix.²³ The toxic ingredients in these products are naphthalene and para-dichlorobenzene, respectively.

Pyrethrins have perhaps the lowest degree of toxicity in birds and warm-blooded mammals. They are often combined with the synergist piperonal butoxide to enhance insecticidal activity.¹¹

General Considerations

Birds suffering insecticide intoxication can manifest symptoms similar to those observed in mammals including sudden anorexia, incoordination, weakness, ataxia, muscle tremors, diarrhea, convulsions, respiratory difficulty and bradycardia.^{23,34,53} Sudden death is usually due to respiratory failure from a single high-dose exposure.³⁸ Other less obvious signs of exposure include reductions in hatchability and egg production. These clinical changes are more common in breeding populations chronically exposed to pesticides.³⁸ While taking a history, clients should always be questioned about their use of insecticides in and around (outside open windows) the home.

A tentative diagnosis of insecticide poisoning is usually possible with a history of recent exposure and appropriate clinical signs. Whole blood acetylcholinesterase activity can be used to confirm a diagnosis of organophosphate intoxication. This test is frequently available in human pediatric laboratories. A sample from an unexposed bird should be included to serve as a control. In quail dusted with carbaryl, plasma cholinesterase activities were depressed up to 27% within six hours.²⁰

There are usually no gross postmortem changes associated with insecticide poisoning, although in some

cases lung edema and hemorrhage may occur. A definitive postmortem diagnosis can be made by tissue analysis of the liver, kidneys, body fat and gastrointestinal contents for insecticide residues. Brain cholinesterase activity can be used to determine if the bird's death was due to an organophosphate intoxication; clinical analysis of tissues may not always be reliable due to the rapid metabolism of these insecticides.³⁸ Any tissues to be analyzed for insecticide residues or acetylcholinesterase activity should be submitted frozen in separate containers.

Treatment for organophosphate toxicosis includes supportive care (supplemental heat, fluids and diazepam to control seizures). Atropine is indicated for cholinergic signs (0.2 to 0.5 mg/kg one-fourth dose IV or IM every three to four hours).^{47,53} Pralidoxime hydrochloride (2-PAM) is antidotal for organophosphate intoxications. 2-PAM was administered to King Pigeons with good results at 10 mg/kg IM.⁵³ The recommended range for mammals is 10 to 100 mg/kg. Steroids may be beneficial for the treatment of pulmonary edema or shock. For maximum effectiveness, antidotal therapy must be initiated within 24 hours of exposure. Organophosphates irreversibly bind to acetylcholinesterase. The more binding that is allowed to occur, the less effective the antidote will be.

Carbamates

Carbamates' mode of action, induced clinical signs and methods of diagnosis and treatment are the same as for organophosphates, although 2-PAM is contraindicated. Over 2,000,000 bird deaths are estimated to occur annually in the United States as a result of the granular carbamate, carbofuran.⁴⁷

Rodenticides

Most rodenticides are of the anticoagulant variety. The first-generation products (warfarin) are less toxic and require longer periods of exposure than the newer generation products (brodifacoum). Clinical signs of toxicity include depression, anorexia, petechiation, epistaxis and subcutaneous hemorrhage. The antidote is vitamin K₁. Some rodenticides contain cholecalciferol or bromethalin and are potentially more difficult to treat than the anticoagulant types. Rodenticide poisoning has been reported in quail and aviary birds when the poison is carried into the bird's food or water by contaminated rodents. Secondary poisonings of raptors from consumption of poisoned rodents (brodifacoum - Talon) have also been reported.¹⁹

Products Mentioned in Text

- a. Bardahl Super Spray, Bardahl, Durdrecht, The Netherlands
- b. Leadcheck kits or swabs, Hybrivet Systems, Inc., Framingham, MA
- c. Edlich Gastric Lavage Kit, Monoject, Sherwood Medical, St. Louis, MO
- d. Formulator, © Wingers Publishing, Inc, Lake Worth, FL

References and Suggested Reading

1. **Allison N, et al:** When pets ingest zinc: How likely is toxicosis? *Vet Med* 777-779, 1989.
2. **Arai M, et al:** Evaluation of selected plants for their toxic effects in canaries. *J Am Vet Med Assoc* 200(9):1329-1331, 1992.
3. **Bond M, et al:** Enrofloxacin in neonates. *J Assoc Avian Vets*, in press 1993.
4. **Bohm J, Hochleitner:** Mycotoxicosis in pet birds: Selected cases. *Proc Europ Assoc Avian Vet*, 1991, p 255-257.
5. **Craigmill AL, et al:** Toxicity of avocado *Persea americana* (Guatemalan var) leaves: Review and preliminary report. *Vet Hum Toxicol* 26(5):381-383, 1984.
6. **DeGernes LA, et al:** Lead poisoning in trumpeter swans. *Proc Assoc Avian Vet*, 1989, p 144-155.
7. **Dieter MP:** Delta-aminolevulinic acid dehydratase enzyme activity in blood, brain and liver of lead-dosed ducks. *Environ Res* 19:127-135, 1979.
8. **Dorman DC, Beasley VR:** Diagnosis of and therapy for cholecalciferol toxicosis. In Kirk RW, Bonagura JD (eds): *Current Veterinary Therapy X, Small Animal Practice*. Philadelphia, WB Saunders Co, 1989, pp 148-152.
- 8a. **Dorman DC:** Anticoagulant, cholecalciferol and bromethalin-biased rodenticides. In Beasley (ed): *Clinics North Am Sm Anim Pract* 20:339-352, 1990.
9. **Dwivedi P, Burns RB:** Ochratoxins in chickens. *Vet Rec* 114(12):295, 1984.
10. **Feldman BF, Kruckenberg SM:** Clinical toxicities of domestic and wild caged birds. In Oehme FW (ed): *Vet Clin No Am Sm Anim Pract* 5(4):653-673, 1975.
11. **Fowler ME:** Disinfectant and insecticide usage around birds and reptiles. In Kirk RW (ed): *Current Veterinary Therapy VIII, Small Animal Practice*. Philadelphia, WB Saunders Co, 1983, pp 606-611.
12. **Fowler ME:** Plant poisonings in pet birds and reptiles. In Kirk RW (ed): *Current Veterinary Therapy IX*, 1986, pp 737-743.
13. **Frank A, Borg K:** Heavy metals in tissues of the mute swan (*Cygnus olor*). *Acta Vet Scand* 20:447-465, 1979.
14. **Fudge AM:** Clinical findings in an Amazon parrot with suspected lead toxicosis. *Cal Vet* 36(5):23-25, 1982.
15. **Gussaway WC, et al:** Zinc toxicity in the mallard duck. *J Wildl Mgt* 36(4):1107-1117, 1972.
16. **Gayley F:** Personal communication. U Calif Toxicology Laboratory, 1992.
17. **Gerlach H:** Drug hypersensitivity. *J Assoc Av Vet* 4(3):156, 1990.
18. **Hargis AM, et al:** Avocado (*Persea americana*) intoxication in caged birds. *J Am Vet Med Assoc* 194(1):64-66, 1989.
19. **Harrison GJ:** Toxicology. In Harrison GJ, Harrison LR (eds): *Clinical Avian Medicine and Surgery*. Philadelphia, WB Saunders Co, 1986, pp 491-499.
20. **Hill EF:** Cholinesterase activity in Japanese quail dusted with carbaryl. *Lab Anim Sci* 29:349-352, 1979.
21. **Howard BR:** Health risks of housing small psittacines in galvanized wire mesh cages. *J Am Vet Med Assoc* 200(11):1667-1674, 1992.
22. **Janssen DL, et al:** Lead toxicosis in three captive avian species. *Proc Am Assoc Zoo Vet*, 1979, pp 40-42.
23. **Klein PN, Galey FD:** The challenge of toxicology investigation in birds. *Proc Assoc Avian Vet*, 1989, pp 139-143.
24. **Klucinski W, Targowski SP:** Ammonia toxicity for mammalian and avian lymphocytes from blood. *Immunopharm* 8(1):47-52, 1984.
25. **Kowalczyk DF:** Lead poisoning. In Kirk RW (ed): *Current Veterinary Therapy IX, Small Animal Practice*. Philadelphia, WB Saunders Co, 1986, pp 145-150.
26. **Krauthwald ME, et al:** Further experiences with the use of baytril in pet birds. *Proc Assoc Avian Vet*, 1990, pp 226-236.
27. **LaBonde J:** Avian toxicology. *Vet Clin No Am Sm Anim Pract* 21(6):1329-1342, Nov. 1991.
28. **LaBonde J:** Pet avian toxicology. *Proc Assoc Avian Vet*, 1988, pp 159-174.
29. **Laitner KS, et al:** Zinc-induced hemolytic anemia caused by ingestion of pennies by a pup. *J Am Vet Med Assoc* 195(1):77-80, 1989.
30. **Lloyd M:** Heavy metal ingestion: Medical management and gastric foreign body removal. *J Assoc Avian Vet* 6(1):25-29, 1992.
31. **Lumeii JT:** Clinicopathologic aspects of lead poisoning of birds: A review. *The Vet Quarterly* Vol 7(2):133-138, 1985.
32. **Lumeii JT, et al:** A new instrument for removing gastric foreign bodies in birds. *Proc Europ Conf Avian Med*, The Netherlands, 1993, pp 91-98.
33. **Lutz ME:** Crown vetch intoxication. *J Assoc Avian Vet* 5:2:73, 1991.
34. **Lyman R:** Neurologic disorders. In Harrison GJ, Harrison LR (eds): *Clinical Avian Medicine and Surgery*. Philadelphia, WB Saunders Co, 1986, pp 486-490.
35. **Mautino M:** Avian lead toxicosis. *Proc Assoc Avian Vet*, 1990, pp 245-247, 1990.
36. **McDonald SE:** Lead poisoning in psittacine birds. In Kirk RW (ed): *Current Veterinary Therapy IX, Small Animal Practice*. Philadelphia, WB Saunders Co, 1988, pp 713-718.
- 36a. **McDonald SE:** Summary of medications for use in psittacine birds. *J Assoc Avian Vet* 3:120-127, 1989.
37. **Minnick PD, et al:** Altered serum elemental concentrations due to laboratory usage of vacutainer tubes. *Vet Hum Toxicol* 24(6):413-414, 1982.
38. **Mohan R:** Dursban toxicosis in a pet bird breeding operation. *Proc Assoc Avian Vet*, 1990, pp 112-114.
39. **Molnar JJ:** Copper storage in the liver of the wild mute swan (*Cygnus olor*). *Arch Pathol Lab Med* 107:629-632, 1983.
40. **Morris P:** Lead and zinc toxicosis in a blue and gold macaw (*Ara ararauna*) caused by ingestion of hardware cloth. *Assoc Avian Vet Newsletter* 6(3):75, 1985.
41. **Muller RD, et al:** The response of chicks, ducklings, goslings, pheasants and poults to graded levels of aflatoxins. *Poultry Sci* 49(5):1346-1350, 1970.
42. **Munn C:** The real macaws. *Animal Kingdom*. Bronx, NY Zool Soc Mag 91(5):26, 1988.
43. **Navarro JL, et al:** Capsaicin effects on consumption of food by cedar waxwings and house finches. *Wilson Bull* 104(3):549-551, 1992.
44. **Perelmann B, Nuttin ES:** Parsley-induced photosensitivity in ostriches and ducks. *Avian Pathol* 17:183-192, 1988.
45. **Olsen GH, et al:** A review of some causes of death of avian embryos. *Proc Assoc Avian Vet*, 1990, pp 106-111.
46. **Osweller GD, et al:** Clinical and Diagnostic Veterinary Toxicology 3rd ed. Dubuque, Kendall/Hunt Publishing Co, 1976.
- 46a. **Osweller GD:** Household and commercial products. In Kirk RW (ed), *Current Veterinary Therapy IX*. WB Saunders Co., Philadelphia, 1986, pp 193-195.
47. **Porter SL, Snead SE:** Pesticide poisoning in birds of prey. *J Assoc Avian Vet* 4(2):84-85, 1990.
48. **Quisenberry KE:** Avian antimicrobial therapeutics. In Jacobson ER, Kollias GV (eds): *Exotic Animals*. New York, Churchill Livingstone, 1988, pp 177-207.
49. **Rae MA, et al:** Pulmonary silicosis in a blue and gold macaw (*Ara ararauna*). *Proc Assoc Avian Vet*, 1991, pp 260-262.
50. **Reece RL, et al:** Zinc toxicity (new wire disease) in aviary birds. *Austr Vet J* 63(6):199, 1986.
51. **Repper R, et al:** The effects of implanted lead shot and various metal on certain parameters in pigeons. *Deutsche Veterinärmedizinische Gesellschaft e.v. München*, 1986, pp 34-37.
52. **Ritchie BW:** Emergency care of avian patients. *Vet Med Report* 2:230-245, 1990.
53. **Ritchie BW:** Treatment of organophosphate toxicosis in *Columba livia*. *Assoc Avian Vet Today* 1(1):23, 1987.
54. **Robinson PT, Richter AG:** A preliminary report on the toxicity and efficacy of levamisole phosphate in zoo birds. *J Zoo Anim Med* 8(1):23-25, 1977.
55. **Roscoe DE, Nielsen SW:** A simple, quantitative test for erythrocytic protoporphyrin in lead-poisoned ducks. *J Wildlife Dis* 15:127-136, 1979.
56. **Rosskopf WJ, Woerpel RW:** Removal of a lead pellet by gizzardotomy (ventriculotomy) in a green-winged macaw. *Vet Med Sm An Clin*, 1982, pp 969-974.
57. **Ruff MD, et al:** Characterization of the toxicity of the mycotoxins aflatoxin, ochratoxin and T-2 toxin in game birds. I. Chukar partridge. *Avian Dis* 34(3):717-720, 1990.
58. **Schlossberg AS, et al:** Muscovy ducklings, a particularly sensitive avian bioassay for T-2 toxin and diacetoxyscirpenol. *Avian Dis* 30(4):820-824, 1986.
59. **Shropshire, et al:** Evaluation of selected plants for acute toxicosis in budgerigars. *J Am Vet Med Assoc* 200(7):936-939, 1992.
60. **Smith JM, et al:** Emtryl toxicity in cockatiels. *Proc 34th West Poult Dis Conf*, 1985, pp 98-100.
61. **Smith JW, Hamilton PB:** Aflatoxicosis in the broiler chicken. *Poult Sci* 49(1):207-215, 1970.
62. **Stauber E:** Effects of increased concentration of inspired oxygen. *Proc Europ Assoc Avian Vet*, 1991, pp 105-114.
63. **Tang K, et al:** Vitamin A toxicity: Comparative changes in bone of the broiler and leghorn chicks. *Avian Dis* 29(2):416-429, 1985.
64. **Takeshita K, et al:** Hypervitaminosis D in baby macaws. *Proc Assoc Avian Vet*, 1986, pp 341-345.
65. **van der Horst H, et al:** Poisoning with lead naphthenate after ingestion of aerosol lubricant in an African grey parrot. *Proc Europ Conf Avian Med & Surg*, The Netherlands, 1993, p 396-404.
66. **van der Mast H, et al:** A fatal treatment of sinusitis in an African grey. *J Assoc Avian Vet* 4(3):3, 189, 1990.
67. **Vaughn S:** Arsenic poisoning in a cockatiel aviary. *Proc Europ Assoc Avian Vet*, 1991, pp 258-263.
68. **Van Sant F:** Zinc toxicosis in a hyacinth macaw. *Proc Assoc Avian Vet*, 1991, pp 255-259.
69. **Wells RE:** Fatal toxicosis in pet birds caused by an overheated cooking pan lined with polytetrafluoroethylene. *J Am Vet Med Assoc* 182(11):1248-1250, 1989.
70. **Wells RE, et al:** Acute toxicosis of budgerigars (*Melopsittacus undulatus*) caused by pyrolysis products from heated polytetrafluoroethylene: Clinical study. *Am J Vet Res* 43(7):1238-1242, 1982.
71. **Windingstad RM, et al:** Fusarium mycotoxins from peanuts suspected as a cause of sandhill crane mortality. *J Wildl Dis* 25(1):38-46, 1989.
72. **Woerpel RW, Rosskopf WJ:** Heavy-metal intoxication in caged birds: parts I,II. *Comp Cont Ed Pract* 4(10):191-196, 1982.
73. **Robb J, Kirkpatrick KS, Marshall DB, Norval M:** Association of toxin-producing fungi with disease in broilers. *Vet Rec* 111:389-390, 1982.
74. **Heathcote JG, Hibbert JR:** Aflatoxins: Chemical and biological aspects. Amsterdam, Elsevier Scientific Publishing, 1978.